

Metastatic Gastrointestinal Stromal Tumor in a Young Male with Neurofibromatosis Type 1

Hanan Ragragui Ouasmin^{1*}, Nassiba Zerrouki¹, Siham Dikhaye^{1,2}, Nada Zizi^{1,2}, Rachid Jabi³, Mohammed Bouziane³

¹Department of Dermatology, Venereology and Allergology, Mohammed VI University Hospital Center, Faculty of Medicine and Pharmacy, Mohammed First University of Oujda, Morocco

²Laboratory of Epidemiology, Clinical Research and Public Health, Oujda, Morocco

³Department of Visceral Surgery, Mohammed VI University Hospital Center, Oujda, Morocco

*Corresponding author: Ouasmin HR, Department of Dermatology, Venereology and Allergology, Mohammed VI University Hospital Center, Faculty of Medicine and Pharmacy, Mohammed First University of Oujda, Morocco, Tel: 00212697917600; E-mail: hanan.ouasmin@gmail.com

Received: April 25, 2020; **Accepted:** May 12, 2020; **Published:** May 19, 2020

Abstract

Neurofibromatosis type 1 (NF1), also called Von Recklinghausen disease, is the most common genodermatosis. Its incidence, prognosis and genetic mechanisms have been the subject of many publications. NF1 patients have an increased risk for developing benign and malignant tumors. Gastrointestinal stromal tumors (GIST) are rare type of cancers, potentially malignant. Patients with NF1 are much more likely to develop GIST with an incidence of 6% to 7% and a median age of 65 years. Cancers are the leading cause of premature death in patients with NF1. We report the case of a young man with neurofibromatosis type 1 who developed a metastatic GIST.

Keywords: *Neurofibromatosis type 1; von Recklinghausen disease; Gastrointestinal stromal tumor; Metastasis; Malignant tumor*

1. Introduction

Neurofibromatosis type 1 (NF1), also called Von Recklinghausen disease, it is the most common genodermatosis [1]. It predisposes to the development of benign and malignant tumors [2]. The NF1- Gastrointestinal stromal tumor (GIST) combination is very rare [2].

Citation: Ouasmin HR, Zerrouki N, Dikhaye S, et al. Metastatic Gastrointestinal Stromal Tumor in a Young Male with Neurofibromatosis Type 1. *Arc Clin Exp Dermatol.* 2020;2(1):107.

GISTs are rare tumors [3]. Their prognosis is good, but some GISTs may behave aggressively with rapid and invasive growth and metastases usually are seen in the liver and peritoneum [2].

2. Case Presentation

We report the case of a forty-one-year-old patient with NF1 history, without similar case in the family and without consanguinity. He presented a distended and painful abdomen associated with anemia and asthenia. The clinical examination revealed seven coffee-milk spots >15 mm, cutaneous neurofibromas, generalized lentiginos and Lisch nodules (FIG. 1). He presented also an abdominal mass of 17 cm, painful and adherent. The abdominal scan revealed an intra-peritoneal mass lateralized to the right of $9.5 \times 13.9 \times 16.5$ cm, pushing the abdominal aorta on the left without invading the adjacent structures (FIG. 2). The patient underwent resection of the mass of small bowel origin (FIG. 3). The histological and immunohistochemical study showed a GIST of 18 cm, expressing the CD 117 with a mitotic index at 22 corresponding to a high metastatic risk (FIG. 4).

The preoperative exploration revealed small bowel nodules whose histological study was for a secondary localization of GIST.

A cerebral magnetic resonance imaging showed an anomaly of the left thalamic signal corresponding of tumor origin. The patient was referred to the oncology hospital for chemotherapy with IMATINIB with a regular clinical and radiological monitoring.

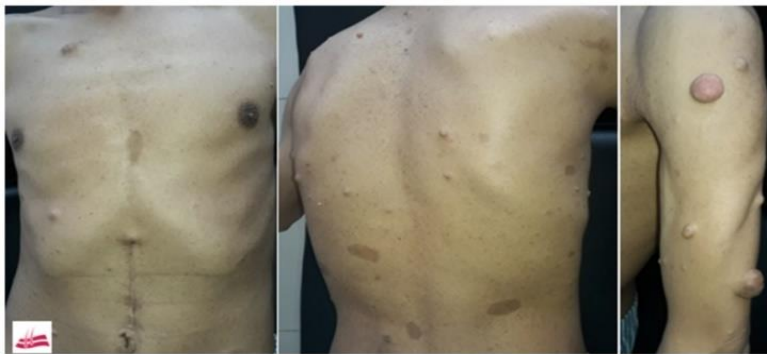

FIG 1. Clinical Signs: Coffee-Milk Spots >15 Mm, Coetaneous Neurofibromas and Generalized Lentiginos.

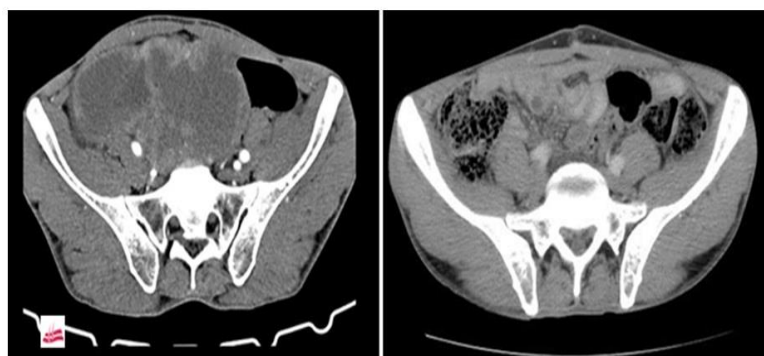


FIG 2: Radiological Appearance of the Mass before and after Surgery.

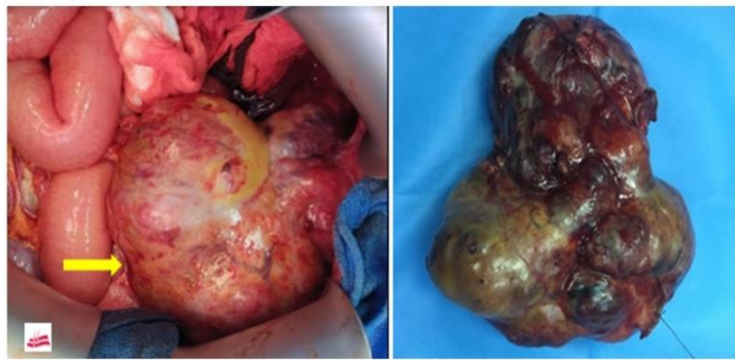

FIG 3. Appearance of the Abdominal Mass Intraoperatively.

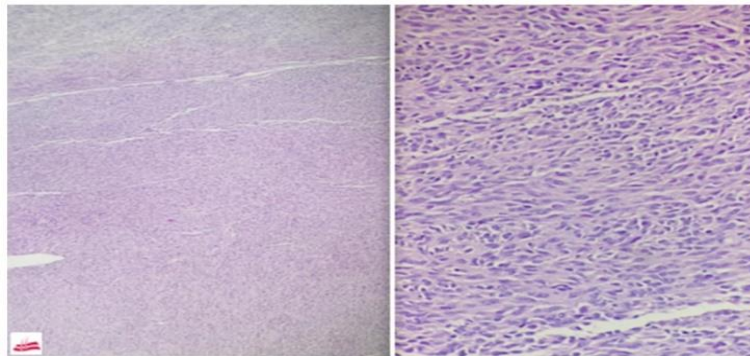


FIG 4. Histology: Microphotograph Showing the Organization in Bundles of Tumor Cells.

3. Discussion

NF1 is caused by a mutation in the NF1 tumor suppressor gene that results in decreased production of the neurofibromin protein, with the risk of developing benign or malignant tumors [3]. According to the practice guideline for treating adults with NF1 by Medical Genetics and Genomics (ACMG), up to 1 in every 1,900 people is affected by NF1 worldwide [4]. It may be hereditary or sporadic [1]. To make the diagnosis of NF1, two of the following clinical features are required: six or more coffee-milk spots with diameters greater than 5 mm in a prepubertal patient and greater than 15 mm in a postpubertal patient, two or more neurofibromas or one plexiform neurofibromas, skinfold (axillary or inguinal) freckling, optic pathway tumor, two or more iris hamartomas, characteristic bony lesion and first-degree relative with neurofibromatosis type 1 [5].

In our case, the diagnostic criteria are the presence of more than six coffee-milk spots >15 mm, generalized lentiginos, more than two neurofibromas as well as the presence of Lisch nodules on ophthalmic examination. The loss of heterozygosity (LOH) at 14q and 22q, as well as the activation of the Ras-MAPK pathway, could contribute to the development of GIST in NF1 [3]. GISTs are rare tumors, with an annual incidence of 10 to 15 per million, usually occur in people aged 55 to 65, which discord with our case. The occurrence of several GISTs is very rare [3] and surgery is the treatment of first intention [2].

The NF1-GIST combination is very rare with an incidence of 6% to 7% [2] and a risk of occurrence 34 times higher in patients with NF1 [4].

4. Conclusion

The evolution of malignancies during NF1 emphasizes the importance of the prevention and regular monitoring of these patients. Furthermore, precocious diagnosis of GIST can lead to effective treatment, hence the importance of knowing this association.

5. Conflict of Interest

None

REFERENCES

1. Poredska K, Kunovsky L, Prochazka V, et al. Triple malignancy (NET, GIST and pheochromocytoma) as a first manifestation of neurofibromatosis type-1 in an adult patient. *Diagn Pathol.* 2019;14:77.
2. Loponen N, Kallionpää RA, Peltonen S, et al. Intestinal tumors in neurofibromatosis 1 with special reference to fatal gastrointestinal stromal tumors (GIST). *Mol Genet Genomic Med.* 2019;7(9):e927.
3. Li K, Tjhoi W, Shou C, et al. Multiple gastrointestinal stromal tumors: analysis of clinicopathologic characteristics and prognosis of 20 patients. *Cancer Manag Res.* 2019;11:7031-8.
4. Kalayanamitra R, Shahid Z, Shah N, et al. The Bleeding Bowel: A Rare Case of Neurofibromatosis Type 1-associated Gastrointestinal Stromal Tumor in a Young Male. *Cureus.* 2019;11(6):e4868.
5. Anderson JL, Gutmann DH. Neurofibromatosis type 1. *Handb Clin Neurol.* 2015;132:75-86.