

Left Renal Cell Carcinoma Presenting as Right Shoulder Dislocation: First Reported Case

Vishal V*, Darsan L, Manikandan M, Shanmughadas KV, Rajeevan AT, Dineshan KM, Venugopalan AV and Cardoza F

Department of Urology, Calicut Medical College, Kerala, India

*Corresponding author: Vishal V, Senior resident, Department of Urology, Calicut Medical College, Kerala, India, Tel: 0495 235 0216; E-mail: drvvs123@gmail.com

Received: February 24, 2018; Accepted: March 06, 2019; Published: March 09, 2019

Abstract

Background: Renal cell carcinoma (RCC) although can present as metastatic disease in almost one third of cases, it presenting as solitary bone lesion as primary sign and symptom is rare event accounting for 0.7%-2.5% only. Bone metastasis mostly presents as bone pain due to lytic lesion or rarely as fracture of axial bone. In this case report we present, RCC presenting as dislocation of shoulder joint of contra lateral side, to our best knowledge is first reported case of RCC presenting as dislocation of contra lateral shoulder joint.

Material and method: Patients had visited in emergency department as severe pain right shoulder.

Result: After initial management of dislocation of shoulder, detailed evaluation and diagnostic work up was done and patient was diagnosed of left renal tumour. Biopsy of bone lesion was reported as metastatic adenocarcinoma and bone scan revealed it to be solitary metastatic lesion. Patient underwent left radical nephrectomy for renal mass and biopsy was reported as clear cell carcinoma. For shoulder metastasis radiotherapy treatment was started. Patient recovered well post operatively with advice for regular follow up and plan to start immunomodulator treatment at later date.

Conclusion: High degree of suspicion in patient presenting as bone pain, fracture of long bones and even dislocation of major joint, especially in young patient with presence of lytic bone lesion, for presence of genitourinary tumour.

Keywords: *Metastatic renal cell carcinoma; Humerus lytic lesion; Shoulder dislocation*

1. Introduction

Renal cell carcinoma is most common genitourinary carcinoma, recently due to advancement of imaging techniques, incidence of incidental detection of renal tumour is increasing [1] but due to late local sign and symptoms and propensity of

lymphatic and blood spread of renal tumour approximately one third of newly diagnosed RCC presents with synchronous metastatic disease [2]. Bone metastasis mostly presents as bone pain due to lytic lesion or rarely as fracture of axial bone. In this case report we present RCC presenting as dislocation of shoulder joint of contra lateral side, to our best knowledge is first reported case of RCC presenting as dislocation of contra lateral shoulder joint.

2. Case Report

In this article we describe a case of 48 years old male presented to emergency department with complaints of acute onset pain and inability of move right shoulder joint. Pain was aggravated on attempted movement of shoulder. He was attended by orthopaedics team; on examination the mobility of right shoulder joint was restricted with tenderness on palpation. On abdomen examination abdomen was soft with mild tenderness and ill-defined mass of variable consistency in left lumbar region. All other systemic examination was within normal limit.

2.1 Investigation

Routine blood test along with USG abdomen and Chest X-ray and X-ray right Shoulder joint was done. X-ray Shoulder joint was suggestive of large lytic lesion of head of right humerus with almost complete replacement of humerus head with the lytic lesion with antero inferior dislocation of shoulder joint. USG abdomen was suggestive of left renal mass involving the lower pole of left kidney with normal contralateral kidney and no liver metastasis. CT abdomen confirmed the USG abdomen report, confirming presence of 8×8×13 cms mass lower pole of left kidney. Mass was abutting left psoas muscle with maintained fat plane. No evidence of thrombus in renal vessel or lymph nodes or visceral metastasis was found.

Bone scan showed lytic lesion at head and surgical neck of right humerus, as the sole metastasis bony lesion. Patient underwent biopsy of shoulder lesion which was reported as adenocarcinoma suggestive of some visceral carcinoma with axial skeleton metastasis (FIG. 1 and 2).

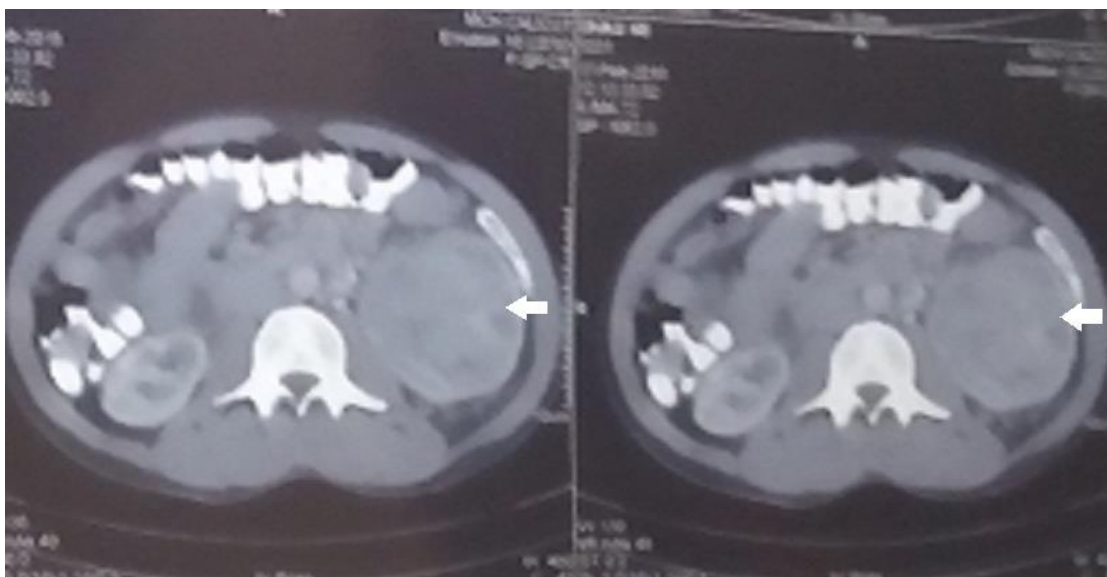


FIG. 1. CT Abdomen + pelvis showing large heterogeneous mass left kidney.

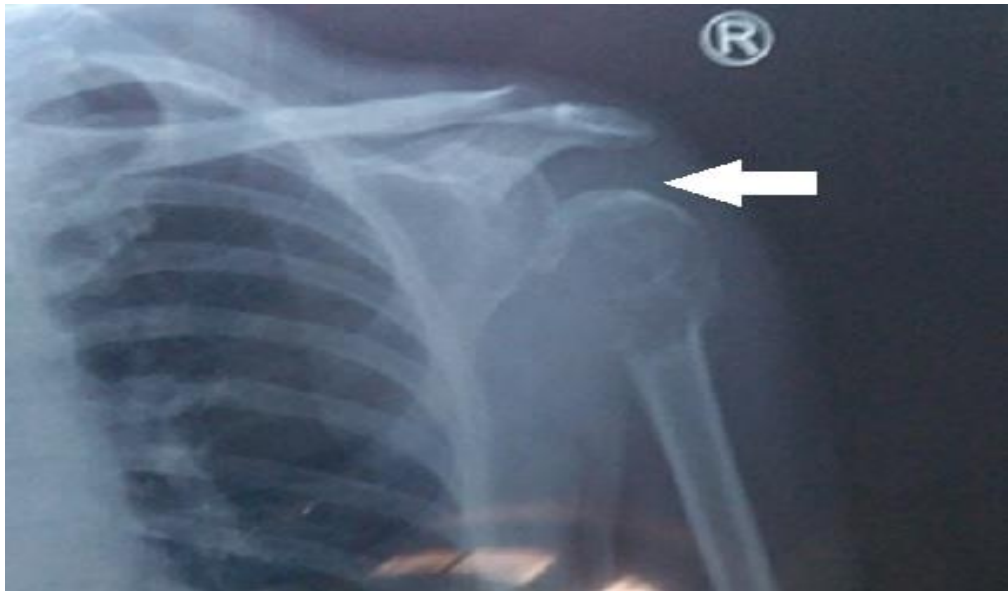


FIG. 2. X-ray right shoulder showing antero inferior dislocation of right shoulder with lytic lesion on head of humerus.

2.2 Management

Initially patient underwent closed reduction of right shoulder joint under anaesthesia as initial measure to reduce pain and discomfort and was advised definitive orthopaedics management after complete work up. Patient was advised arm sling for at least 3 weeks.

For the renal lesion patient underwent left radical nephrectomy with lymph node sampling. The tumour was 8×8×10 cms involving mid and lower pole of left kidney and was penetrating renal capsule and infiltrating renal fat with two enlarged paraaortic lymph nodes. Adrenal was free of tumour and no evidence of thrombus in renal vessels. Histopathological examination revealed clear cell carcinoma with Furhman grade I, stage T3b with only reactive changes in the lymph nodes. Patient had uneventful post-operative period.

Orthopaedics and radiotherapy consultation were done for management of shoulder lesion and patient was planned for radiotherapy followed by shoulder joint replacement surgery if feasible.

3. Discussion

In renal cell carcinoma (RCC) although bone metastasis is only next to lung and liver, they rarely are primary signs of RCC. Isolated bone metastasis accounts for 0.7%-2.5% only [3] and of these rib and scapular metastasis are common [4] but isolated humerus metastasis presenting as lytic lesion of head leading to shoulder dislocation is extremely rare event. Swanson et al. studied 947 patients with renal cell carcinoma and skeletal metastasis was found in 26.7% of patients which mostly involved spine, pelvis and proximal femur. On detailed review of literature RCC presenting as shoulder mono arthritis

[5] was found but to my best of my knowledge there is no case reported as shoulder joint dislocation as a result of RCC metastasis [6].

Skeleton related event (SRE) in case of skeleton metastasis comprises mostly of pathological fracture, bone pain, impending fracture or nerve root compression but rarely of major joint dislocation. These skeleton related event impair patient quality of life [7] and are diagnostic and therapeutic challenges during management of renal tumour. Bone metastases for RCC can be of three types osteolytic, osteoblastic and mixed. Of these osteolytic type is most common. Among all metastatic disease, solitary bony metastatic has better prognosis with 5 year survival of 35%-60%.

Kominsky et al. [8] stated that tumour spread and bone destruction can be stimulated by transforming growth factor-beta1 [TGF-1] in vivo thus TGF1 inhibitor can be potential therapy to control metastasis [8]. Term malignant shoulder syndrome was coined by Micheal et al to describe a predilection of renal cell cancer for metastasizing to shoulder girdle, scapula being most commonly involved structure, who described bilateral scapular metastasis of RCC.

Management of metastatic renal carcinoma constitutes of cytoreductive radical nephrectomy for control of local disease followed by immunomodulator for example tyrosine kinase inhibitor, sunitinib, 50 mg per day for 4 weeks with 2 week gap for 1 year or till unmanageable side effects appear. For metastatic bone disease biopsy followed by definitive management in form of internal fixation or currtage or radiotherapy is done.

Radiotherapy is used to provide palliative treatment in case painful bone metastasis and nerve or spinal cord decompression. Advances in radiotherapy technologies such as intensity modulation RT, stereotactic body RT and stereotactic radiosurgery [SRS], have increased local control to 90% for SRS [9]. As in this case report shoulder dislocation was presenting feature closed reduction of dislocation under anaesthesia was undertaken as initial treatment.

Various treatment modality can be used to reduce Skeleton related event for Example Bisphosphonates (Zoledronic acid) or RANKL inhibitors (Donesumab). Denosumab was found to be superior to Zoledronic acid in delaying time to first SRE by a median 8.21 months and reduced the risk of first SRE by 17%. Denosumab did not require monitoring, dose modification, or withholding based on renal functions and it was not associated acute phase reaction [10]. Overall prognosis of patient with advanced RCC is poor; possibly due to lack of effective chemotherapy, emphasizes on importance of early detection and prompt treatment of primary lesion in its early stage.

4. Conclusion

High degree of suspicion in patient presenting as bone pain, fracture of long bones and even dislocation of major joint, especially in young patient with presence of lytic bone lesion, for presence of genitourinary tumour. Prompt reduction of dislocated joint after detailed discussion with patient regarding risk of fracture during the manipulation should be done strictly under anaesthesia. Detailed diagnostic and metastatic work is required for correct diagnosis, staging and planning for proper management of primary lesion. Management of such lesion should be team effort of orthopaedician, radiotherapist and urologist.

5. Conflict of Interest

All authors declare no relationship with other people and organisations of this work.

6. Ethical Approval

Authors obtained from the patient's consent for his data to use publication to case report.

REFERENCES

1. Patard JJ, Rodriguez A, Rioux-Leclercq N, et al. Prognostic significance of the mode of detection in renal tumours. *BJU Int.* 2002;90(4):358-63.
2. Doshi D, Saab M, Singh N. Atypical presentation of renal cell carcinoma: a case report *J Med Case Reports.* 2007;1:26.
3. Jung ST, Ghert MA, Harrelson JM, et al. Treatment of osseous metastases in patients with renal cell carcinoma. *Clin Orthop Relat Res.* 2003;409:223-31.
4. Gurney H, Larcos G, McKay M, et al. Bone metastases in hypernephroma. Frequency of scapular involvement. *Cancer.* 1989;64(7):1429-31.
5. Placed IG, Alvarez-Rodriguez R, Pombo-Otero J, et al. Metastatic renal cell carcinoma presenting as shoulder monoarthritis: diagnosis based on synovial fluid cytology and immunocytochemistry. *Acta Cytol.* 2010;54(5):730-3.
6. Swanson DA, Orovan WL, Johnson DE, et al. Osseous metastases secondary to renal cell carcinoma. *Urology.* 1981;18(6):556-61.
7. Onishi T, Machida T, Masuda F, et al. Clinical study of renal cell carcinoma with bony metastasis: comparative study with lung metastasis. *Hinyokika Kyo.* 1989;35(7):1113-5.
8. Kominsky SL, Doucet M, Brady K, et al. TGF-beta promotes the establishment of renal cell carcinoma bone metastasis. *J Bone Miner Res.* 2007;22(1):37-44.
9. Henry DH, Costa L, Goldwasser F, et al. Randomized, double-blind study of denosumab versus zoledronic acid in the treatment of bone metastases in patients with advanced cancer (excluding breast and prostate cancer) or multiple myeloma. *Clin Oncol.* 2011;29(9):1125-32.
10. Reichel LM, Pohar S, Heiner J, et al. Radiotherapy to bone has utility in multifocal renal carcinoma. *Clin Orthop Relat Res.* 2007;459:133-38.