

Dental implant placement procedure with simultaneous bone augmentation: The Pros and Cons, A Case Report

Abhishek Singh Nayyar*

Department of Oral Medicine and Radiology, Saraswati-Dhanwantari Dental College and Hospital and Post-Graduate Research Institute, India

*Corresponding author: Nayyar AS, Department of Oral Medicine and Radiology, Saraswati-Dhanwantari Dental College and Hospital and Post-Graduate Research Institute, Parbhani, Maharashtra, India, Tel: +91-98509 04067; E-mail: singhabhishekndls@gmail.com

Received: September 11, 2019; Accepted: October 18, 2019; Published: October 29, 2019

Abstract

Dental implantology has been considered as one of the most accepted treatment modalities for rehabilitation of missing teeth. The deficiency of the remaining supporting bone volume, though, is considered to be the primary concern in certain situations for avoiding implant placements. The solution to this problem lies in re-establishing the ridge volume consistent with the prosthetic design and with suitable load-bearing lamellar bone for long-term stability of the implant. The rehabilitation of large bone defects can be achieved with various types of grafting materials, natural or, synthetic. The use of autologous grafts exhibits the highest success rates amongst these and autogenous bone grafts are considered the gold standard because their osteogenic, osteo-inductive and osteo-conductive properties maximize the success of graft incorporation. The present case report describes the case of a 35-year-old female patient who reported seeking treatment for her missing front tooth, right maxillary central incisor, which she had lost as a result of trauma at the age of 30 years. Clinical and radiographic examination revealed a severe vertical labial bone defect requiring vertical and horizontal bone augmentation. The amount of bone available was inadequate for an implant-supported prosthesis. Hence, vertical and horizontal bone augmentation with guided bone regeneration was planned in the region with simultaneous placement of the endosseous implant. The present case report, thus, demonstrates the successful use of vertical and horizontal bone augmentation procedure conducted with the help of guided tissue regeneration (GTR) and simultaneous endosseous implant placement.

Keywords: *Vertical and horizontal bone augmentation procedures; Guided tissue regeneration (GTR); Dental implant therapy; Endosseous implants*

1. Introduction

Dental implantology has been considered as one of the most accepted treatment modalities for rehabilitation of missing teeth. The deficiency of the remaining supporting bone volume, though, is considered to be the primary concern in certain situations for avoiding implant placements [1]. The solution to this problem lies in re-establishing the ridge volume consistent with the prosthetic design and with suitable load-bearing lamellar bone for long-term stability of the implant [2]. Bone grafting techniques are widely used in the restoration of the atrophic maxillary bone prior to the placement of dental implants. Atrophy of the maxillary bone is caused by trauma, malignant diseases, oral infections, congenital absence of teeth or, the tri-dimensional alveolar ridge resorption process subsequent to following routine dental extractions [3]. The rehabilitation of large bone defects can be achieved with various types of grafting materials, natural or, synthetic. The use of autologous grafts exhibits the highest success rates amongst these and autogenous bone grafts are considered the gold standard because their osteogenic, osteo-inductive and osteo-conductive properties maximize the success of graft incorporation [4,5].

Regardless of the donor site, though, approximately 4-6 months of healing period is required for the implants which is accomplished by using two-staged technique of implant placements. This technique uses autogenous bone grafts harvested at the time of surgery and is the most frequently used grafting technique because of its general clinical success and predictability in terms of implant site development. One of the important parameters for optimizing the bone regeneration is space maintenance, hence, collagen membranes are widely utilized during such procedures.

2. Case Report

A 35-year-old female patient reported seeking treatment for her missing front tooth, her right maxillary central incisor, which she had lost as a result of trauma at the age of 30 years. The patient was in good health with no positive medical history, good oral hygiene maintenance and a strong desire to replace her missing tooth with a permanent fixed prosthesis. Clinical (FIG. 1) and radiographic examination revealed a severe vertical labial bone defect requiring vertical and horizontal bone augmentation. The amount of bone available was inadequate for an implant-supported prosthesis. Hence, vertical and horizontal bone augmentation with guided bone regeneration was planned in the region with simultaneous placement of the endosseous implant. An autograft from the chin was planned taking consent from the patient regarding creation of a second surgical site. Later, for esthetic purpose, soft tissue augmentation was planned for which the patient refused. The complete treatment procedure was explained to the patient and a duly signed consent was obtained.

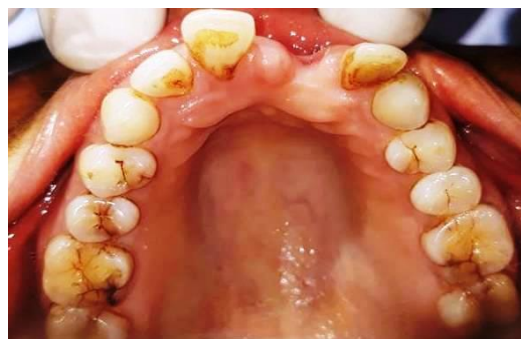

Fig. 1. Pre-operative view of the defect.

3. Surgical Procedure

The corresponding surgical procedure was performed in sterile surgical conditions. Pre-operatively, the oral cavity was decontaminated using 0.2% chlorhexidine mouth rinse for 1min and the peri-oral area was disinfected with 5% povidone iodine solution. The site was anesthetized using 2% lignocaine with 1:80,000 adrenaline. A full thickness crestal incision, two crevicular incisions and a vertical releasing incisions on the distal extent of the flap were made and a full thickness muco-periosteal flap (FIG. 2) was reflected. On reflection of the flap, absence of the labial bone plate was observed with a deep vertical defect. A second surgical site in the lower labial sulcus was, then, created to collect an autograft from the mandibular symphysis region (chin bone in inter-foraminal region). The area was adequately anesthetized using bilateral inferior alveolar nerve block and local infiltration with local anesthetic solution. A horizontal incision was made in the lower vestibule. The incision was directed in the apico-lingual direction toward the bone. Below this point, a full thickness muco-periosteal flap (FIG. 3) was reflected toward the base of the mandible keeping the most inferior aspect of the mentalis muscle intact. With the help of auto bone collector (HIOSSSEN Implant System) (FIG. 4), bone chips with adequate thickness were collected from the chin bone (FIG. 5). The soft tissue superior to the initial access incision was elevated by few millimetres to reduce tension on the flap by edema and lip movement. The vestibular incision was, then, sutured with non-resorbable sutures (FIG. 6) using interrupted suturing techniques.

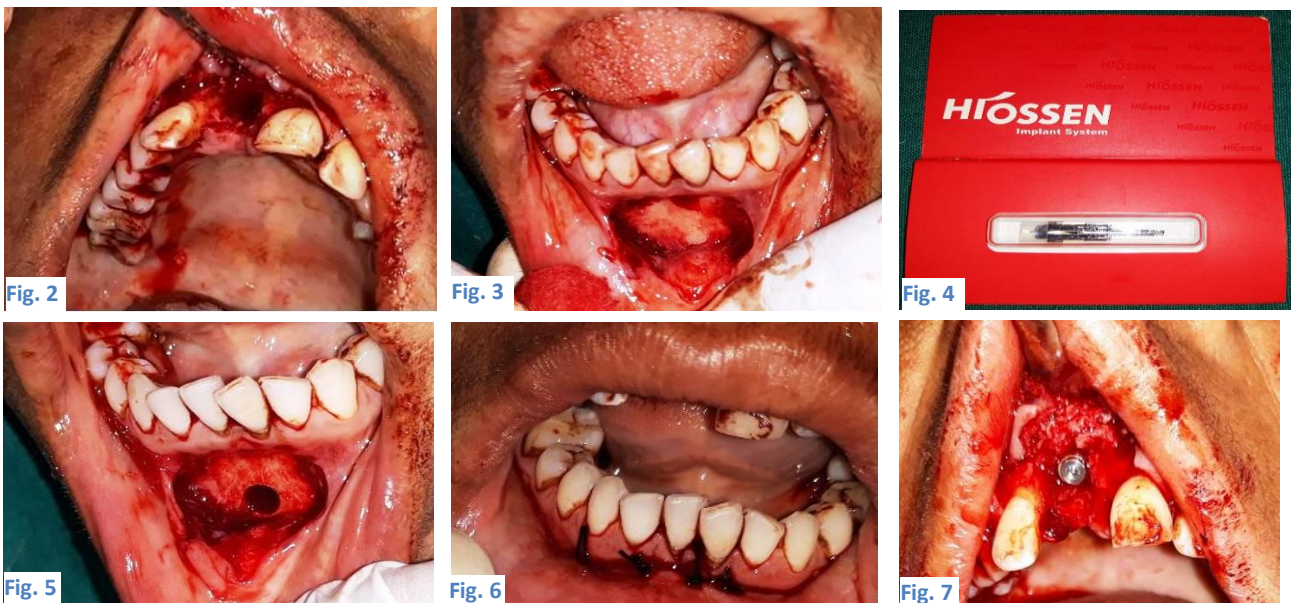


FIG. 2. Flap reflection (from the labial side of the defect), FIG. 3. Preparation of the second surgical site, FIG. 4. Auto bone collector (HIOSSSEN Implant System), FIG. 5. Collection of autograft from the second surgical site using bone collector, FIG. 6. Sutures placed to close the wound created at the second surgical site and FIG. 7. Implant placed at the primary surgical site with defect.

The osteotomy site for implant placement was, then, prepared. A standard 2 mm twist drill was used in the Myriad Equinox Implant System. A standard osteotomy was done with the pilot drill and twist drills along with direction indicators and depth gauges. A Myriad Equinox Implant, 5 mm in diameter and with 13 mm length (FIG. 7) was placed at the site. Cover screw was placed. The labial defect was grafted using a combination of chin bone autograft and Hydroxyapatite graft (G-graft,

Surgiwear, India) (FIG. 8) with the autograft placed first and the allograft over it with the help of a syringe (FIG. 9). The graft was secured in place with collagen membrane (FIG. 10). Following this, the surgical site was closed with the flap and primary wound closure was obtained with interrupted sutures (FIG. 11). An immediate post-operative radiograph was taken as baseline for future comparisons to assess bone healing (FIG. 12). Post-surgical Instructions and Oral Hygiene Care: Post-surgical instructions were given to the patient. Chemical plaque control with 1% chlorhexidine (CHX) (1 min mouth rinse 3 times a day) was instituted for 2 weeks along with non-steroidal anti-inflammatory drug (NSAID), Diclofenac 75 mg, 3 times a day for 3 days initially and then, si opus sit (as and when required) thereafter and antibiotic, Amoxicillin 500 mg, 3 times a day for 5 days. A weekly follow-up was done initially while the sutures were removed after 10 days following an uneventful healing. This was followed by a once every month follow-up till 6 months when the site was inspected radiographically (FIG. 13) for adequate osseointegration and the second stage surgery was performed with placement of the healing abutment. A metal ceramic crown was, subsequently, fabricated and cemented.



Fig. 8



Fig. 9

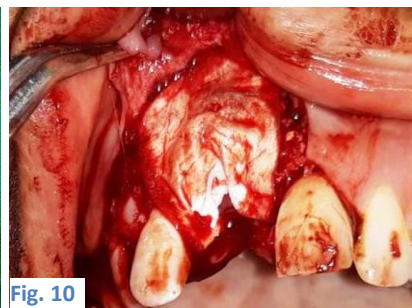

Fig. 10

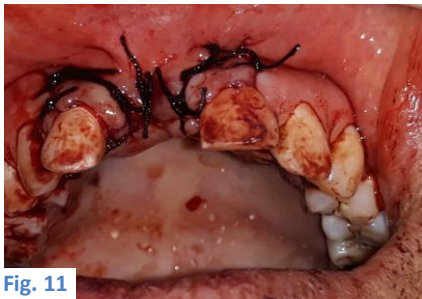

Fig. 11

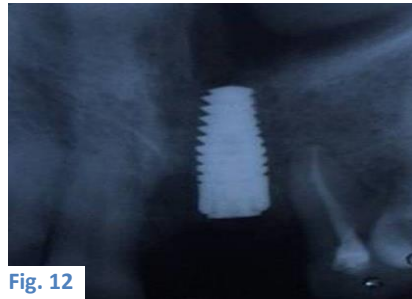


Fig. 12



Fig. 13

FIG. 8. Hydroxyapatite alloplast material, FIG. 9. Loaded syringe with Hydroxyapatite alloplast material, FIG. 10. Placement of graft (auto- and allo-graft) along with collagen membrane for guided tissue (bone) regeneration, FIG. 11. Sutures placed to close the wound created at the primary surgical site with defect, FIG. 12. Immediate post-operative radiograph and FIG. 13. Post-operative radiograph taken at 6-months' follow-up visit.

4. Discussion

Implant placement requires an adequate quantity and quality of bone. The anatomic limitations of the residual alveolar ridge may make the insertion of dental implants difficult. Implants placed into the alveolar bone sites, previously augmented with graft material, have been associated with a high success rate [6,7]. The need for multiple surgeries with more procedural and post-procedural healing times, though, put serious disadvantage in such staged procedures of implant placements. Though not abundant, limited studies conducted in the recent past with few case reports reporting successful treatment outcomes have shown that predictable treatment outcomes could be achieved in cases where dental implant placement with simultaneous bone augmentation was done. The present case report demonstrates a similar case wherein the successful use of vertical and

horizontal bone augmentation procedure conducted with the help of guided tissue regeneration (GTR) and simultaneous endosseous implant placement was done.

Allografts and alloplasts serve a space-maintenance role whereas fresh frozen transplants confer the risk of disease transmission. Autogenous bone grafts, thus, are still considered the gold standard, especially, when larger volumes of tissue restorations are required [8]. Iliac and calvarial grafts have often been seen to possess varying rates of complications including increased risk of infections, mobility impairment and hernias [9-11]. On the contrary, autogenous chin bone ridge augmentation has been proposed to be a reliable alternative method for the management of severely defective socket bone tissues [12].

The bone tissue obtained by means of bone collectors as was done in the present case was already in a particulate state, thus, reducing the operation time and the probability of contamination since in the present case, there was no bone crusher used. Also, the use of barrier membrane has been proposed to be an efficient way of preventing surface resorption. In the present case, collagen membrane was utilized for an effective guided bone regeneration procedure. Several in-vitro studies on cell-scaffold interactions and tissue synthesis as well as in-vivo studies have revealed excellent biological performance of collagen. The membrane must be cut and trimmed to adapt to the anatomy of the ridge and applied over the defect in order to cover the bone graft. Due to the hydrophilic properties of the collagen membrane, it is supposed to stick to the bone surface once wetted either with saline or, blood eliminating the need for fixation screws or, tacks for stabilization in most of the cases [13-15].

The usual protocol of conventional implant placement procedures, though, requires two surgical procedures, first, for bone augmentation and the second, for implant placement at an interval of about 3-4 months, however, in the present case, bone augmentation was done with simultaneous implant placement which saved the time for second invasive procedure. Also, bone collector used in the present study helped in conservative retrieval of the autograft. Thus, the surgical technique demonstrated here for obtaining particulate intra-oral autogenous bone material proved to be simple, efficient and safe. However, as autograft was used in the present study, morbidity of the second surgical site created for harvesting autograft was the major limitation.

5. Conclusion

Proper case selection and accurate surgical planning are the main pre-requisites for any successful graft harvesting procedure. A long-term, longitudinal study is indicated, though, to evaluate the implant durability after loading and the eventual success of implant placement in such cases with severe bone defects. Nevertheless, the use of autogenous bone grafts, also, presents considerable drawbacks including the need for creating a second surgical site, high morbidity at the donor site, limited quantity of bone that can be obtained, unpredictable quality of bone, blood loss, increased operative time and the possibility of infection at the donor site, subsequently, leading to severe destruction of bone in certain situations wherein any breach in a strict aseptic protocol is observed, however, seeing the advantages and the healing and regeneration potential with least chances of rejection of the graft material harvested mandate the need for further studies to be conducted ensuring the long-term follow-up in such cases to see the successful clinical outcomes and the possible failures and the reasons behind to

improve the technique for future cases with a proper case selection and accurate surgical planning being the pre-requisites for success in such clinical situations.

REFERENCES

1. Andersson B, Odman P, Carlsson GE. A study of 184 consecutive patients referred for single-tooth replacement. *Clin Oral Implants Res.* 1995;6(4):232-7.
2. Buser D, Dahlen C, Schenk RK. *Guided Tissue Regeneration in Implant Dentistry.* Chicago: Quintessence Publishing Co. Inc., USA; 1994.
3. Pereira E, Messias A, Dias R, et al. Horizontal resorption of fresh-frozen cortico-cancellous bone grafts in the reconstruction of the atrophic maxilla at 5 months. *Clin Implant Dent Rel Res.* 2015;17(Suppl 2):e444-58.
4. Zetola AL, Verbicaro T, Littieri S, et al. Recombinant human bone morphogenetic protein type 2 in the reconstruction of atrophic maxilla: Case report with long-term follow-up. *J Indian Soc Periodontol.* 2014;18(6):781-5.
5. Albrektsson T, Johansson C. Osteo-induction, osteo-conduction and osseo-integration. *Eur Spine J.* 2001;10(Suppl 2):S96-101.
6. Carinci F, Brunelli G, Zollino I, et al. Mandibles grafted with fresh-frozen bone: An evaluation of implant outcome. *Implant Dent.* 2009;18(1):86-95.
7. Franco M, Tropina E, De Santis B, et al. A 2-year follow-up study on standard length implants inserted into alveolar bone sites augmented with homografts. *Stomatologija.* 2008;10(4):127-32.
8. Hollinger JO, Brekke J, Gruskin E, et al. Role of bone substitutes. *Clin Orthop Relat Res.* 1996;324:55-65.
9. Nkenke E, Neukam FW. Autogenous bone harvesting and grafting in advanced jaw resorption: Morbidity, resorption and implant survival. *Eur J Oral Implantol.* 2014;7(Suppl 2):S203-17.
10. Dasmah A, Thor A, Ekestubbe A, et al. Particulate vs. block bone grafts: Three-dimensional changes in graft volume after reconstruction of the atrophic maxilla: A 2-year radiographic follow-up. *J Craniomaxillofac Surg.* 2012;40(8):654-9.
11. Navarro Cuellar C, Caicoya SJ, Acero Sanz JJ, et al. Mandibular reconstruction with iliac crest free flap, nasolabial flap and osseo-integrated implants. *J Oral Maxillofac Surg.* 2014;72(6):1226.e1-15.
12. Omara M, Abdelwahed N, Ahmed M, et al. Simultaneous implant placement with ridge augmentation using an autogenous bone ring transplant. *Int J Oral Maxillofac Surg.* 2016;45(4):535-44.
13. Urist MR. Bone formation by auto-induction. *Sci.* 1965;150(3698):893-9.
14. Geesink RGT, Hoefnagels NHM, Bulstra SK. Osteogenic activity of OP-1 bone morphogenetic protein (BMP-7) in a human fibular defect. *J Bone Joint Surg Br.* 1999;81(4):710-8.
15. Heckman JD, Ehler W, Brooks BP, et al. Bone morphogenetic protein but not transforming growth factor enhances bone formation in canine diaphyseal non-unions implanted with a biodegradable composite polymer. *J Bone Joint Surg Am.* 1999;81(12):1717-39.