

Axial Torsion of a Large Meckel's Diverticulum in an Adolescent with Developmental Delay

Elena Dingle¹, Mahrukh Shah¹, Mario Olivo², Don Kohan³ and Ratna B Basak^{1,4*}

¹Department of Pediatrics, Brookdale Hospital Medical Center, Brooklyn, NY, United States

²Department of Emergency Medicine, Brookdale Hospital Medical Center, Brooklyn, NY, United States

³Department of Surgery, Brookdale Hospital Medical Center, Brooklyn, NY, United States

⁴Flushing Hospital Medical Centre, Flushing, NY, United States

*Corresponding author: Basak RB, Department of Pediatrics, Brookdale Hospital Medical Center, Brooklyn, NY, United States, Tel: +1718-240-5893; E-mail: ratnabimalbasak@gmail.com

Received: February 14, 2020; **Accepted:** March 05, 2020; **Published:** March 12, 2020

Abstract

Meckel's diverticulum (MD) is the most common congenital anomaly of the gastrointestinal tract which is caused by incomplete obliteration of omphalomesenteric duct. It usually presents before the age of 2 years and is twice as common in females. In this report, we present a case of an axial torsion and gangrene of a large MD in a 15-year-old mentally challenged adolescent.

Keywords: *Meckel's diverticulum; Axial torsion; Autism; Developmental delay*

1. Introduction

Meckel's diverticulum (MD) is a remnant of omphalomesenteric duct that may remain silent or can have life-threatening complications. Majority of symptomatic Meckel's diverticula are lined by an ectopic mucosa that causes painless rectal bleeding or ulceration. Less common complications include partial or complete obstruction. Older children can develop diverticulitis leading to perforation and peritonitis.

2. Case Report

A 15-year-old male with history of autism, moderate developmental delay, presented with one-day history of generalized abdominal pain, nausea, vomiting, decreased oral intake and urinary output. Medical history is significant for failure to

thrive, constipation, recurrent episodes of non-specific abdominal pain with poor oral intake for one year. In the past, the pain episodes usually lasted up to 24 hours and were associated with moderate dehydration requiring hospitalization. The Emergency Room vitals: HR: 107, Resp: 20, BP: 106/60, Temp: 39.1, Sat: 99%. Physical exam revealed generalized abdominal tenderness with rebound and guarding in the mid-abdomen.

Labs showed the white cell count of 11,700/ml with 86.5% neutrophils. X-Ray abdomen did not show any pathology (FIG. 1). Abdominal ultrasonogram showed free fluid in the para-colic gutter. CT scan of abdomen revealed possible enteritis vs small bowel obstruction (FIG. 2). He was taken up for emergent laparotomy. Abdominal cavity was accessed through a midline incision around the umbilicus. Upon entry, reactive ascites was noted. Findings included a large necrotic MD 10 × 10 cm long and wide, which was torsed several times along its narrow pedicle. It was 2 cm in greatest dimension, located at about 35 cm from the ileocecal valve. Focal mesenteric lymphadenopathy was noted at the site of torsion. The diverticulum was de-torsed. No mass was palpated or bleeding noted in the MD or in the attached small bowel. Mesentery of the diverticulum was isolated, divided, ligated with 2-0 silk tie and using the blue load endoGIA stapler; the diverticulum was excised at its base without compromising the bowel lumen. Staple line was then sewn over using 3-0 silk running interlocking suture for hemostasis. Incidental appendectomy performed due to high risk of complicated appendicitis in the young patient with limited communication skills and multifactorial abdominal symptomatology. Histopathological examination showed hemorrhagic necrosis of MD consistent with torsion, with no evidence of tumor or heterotopic tissue. Patient's post-operative period and follow-ups were uneventful.

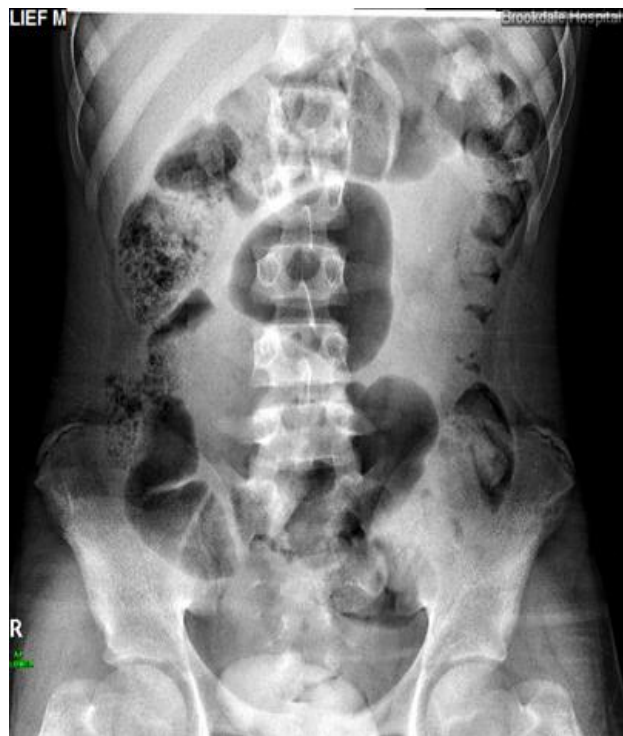

FIG. 1. XR abdomen. Frontal view. No pneumoperitoneum. No bowel dilatation. Moderate amount of fecal material seen throughout the colon. No abnormal calcifications.

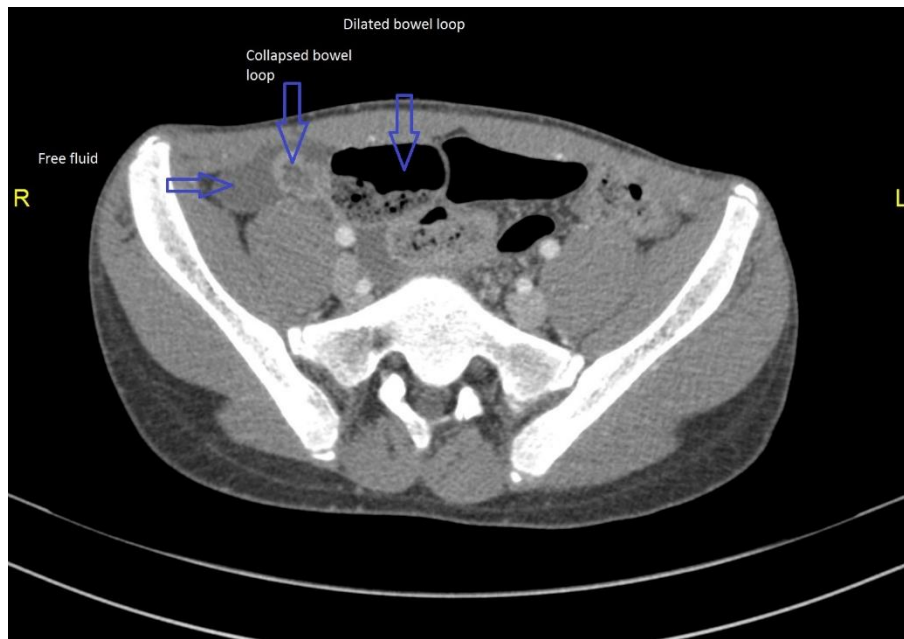


FIG 2. CT scan of abdomen with contrast. Mild free fluid in the abdomen, greatest in the right paracolic gutter and pelvis usual and is likely reactive. Suggestion of bowel obstruction with a point of apparent transition at the right pelvis. The collapsed small bowel suggests wall enhancement and may reflect enteritis. An adhesion is not excluded.

3. Discussion

The incidence of MD is around 1%. About 16% of MD can be symptomatic with the majority of patients older than 10 years [1]. MD is usually short and wide, on average 2.9 cm long and 1.9 cm wide [2]. MD in our patient was huge, measuring 10cms x 10 cm, which is rare.

MD can be asymptomatic or may have a dramatic presentation. The most common way it presents in children is with intestinal obstruction which is seen in 40%-86% of cases followed by bleeding and diverticulitis in a third of cases [1,3]. In adults, the majority presents with bleeding (38%), followed by obstruction (34%) and diverticulitis (28%) [1].

Axial torsion of MD is a rare presentation. A literature review of 40 years found 16 adult cases and 10 pediatric cases of MD with axial torsion. In the pediatric population, most reported cases were in the adolescent period. The youngest patient was a 1-year-old boy [4]. Narrow base of MD, excessive length, attachment to the umbilicus or to the ileal mesentery are the predisposing factors to axial torsion [2,3,5]. Gangrene of MD after axial torsion is an extremely rare complication in children. Our case represents the 4th reported case of gangrenous MD in the pediatric population [2,6,7].

Histopathologic findings of excised MD showed ectopic tissue in 59% of cases, with gastric mucosa being the most common (52%), followed by pancreatic (5%), and colonic tissue (2%) [1]. Our patient's MD histology did not reveal any ectopic tissue.

Axial torsion of MD is usually characterized by sudden abdominal pain with bilious vomiting [3,5]. One case of a 51-year-old patient reported a 3-year history of intermittent colicky abdominal pain which was retrospectively thought to be caused by repeated episodes of torsion and ischemia [8]. Our case is probably the single reported pediatric case of axial MD torsion with history of recurrent abdominal pain and failure to thrive leading us to ponder if the previous episodes were attributed to intermittent torsion of MD. The giant size of MD, torsion several times along its axis could possibly explain the prolonged course in our developmentally challenged adolescent.

Less than 10% of symptomatic MD are diagnosed preoperatively [9]. A preoperative diagnosis is difficult due to overlapping clinical and radiologic features of other acute conditions of the abdomen [10]. A high index of suspicion is warranted in diagnosing MD especially in young or developmentally challenged children.

As per Zani et al [11], mortality related to MD is seen mainly in children. There is still no consensus whether to remove an asymptomatic MD or leave it in situ in pediatric or adult population as no meta-analysis was done showing the preference of one approach over the other [1,11]. In symptomatic patients, early surgery is beneficial in preventing significant morbidity and mortality [5].

It is also unclear when to perform a simple diverticulectomy vs doing a segmental resection of the attached small bowel in cases when the MD has wide pedicle, is associated bleeding or palpable mass in the adjacent small bowel [1]. Laparoscopic approach is considered the first choice in removing an axial torsed MD [1,3].

As per the systematic review by Healy et al [12], the decision to proceed with an incidental appendectomy in children usually depends on surgeon's foresight, considering the associated comorbidities and the risks of future appendicular pathology.

4. Conclusion

The incidence of axial torsion of MD is more in the adolescents. High vigilance is prudent when screening children with developmental delays when they present with signs of acute abdomen. Imaging studies can be inconclusive; diagnostic laparoscopy remains the procedure of choice for removing a MD.

5. Conflict of Interest

None

6. Author Contribution

Dr. Dingle conceptualized, wrote, edited, and approved the final version of the manuscript

Drs. Shah and Basak wrote, edited and approved the final version of the manuscript

Drs. Kohan and Olivio edited and approved the final version of the manuscript

REFERENCES

1. Park JJ, Wolff BG, Tollefson MK, et al. Meckel diverticulum: The Mayo Clinic experience with 1476 patients (1950-2002). *Ann Surg.* 2005;241(3):529-33.

2. Limas C, Seretis K, Soultanidis C. Axial torsion and gangrene of a giant Meckel's diverticulum. *J Gastrointest Liver Dis.* 2006;15(1):67-8.
3. Rattan KN, Singh J, Dalal P, et al. Meckel's diverticulum in children: Our 12-year experience. *Afr J Paediatr Surg.* 2016;13(4):170-4.
4. Tassinari D, Cimatti AG, Tani G, et al. A common case of gastroenteritis in a child followed by an axial torsion of Meckel diverticulum: a rare and unusual complication. *BMJ Case Rep.* 2013;2013:bcr2012006656.
5. Nose S, Okuyama H, Sasaki T, et al. Torsion of Meckel's Diverticulum in a Child. *Case Rep Gastroenterol.* 2013;7(1):14-8.
6. Eser M, Oncel M, Kurt N. Gangrene secondary to axial torsion in a patient with Meckel's diverticulum. *Int Surg.* 2002;87(2):104-6.
7. Malhotra S, Roth DA, Gouge TH, et al. Gangrene of Meckel's diverticulum secondary to axial torsion: a rare complication. *Am J Gastroenterol.* 1998;93(8):1373-15.
8. Tan YM, Zheng ZX. Recurrent torsion of a giant Meckel's diverticulum. *Dig Dis Sci.* 2005;50(7):1285-7.
9. Tenreiro N, Moreira H, Silva S, et al. Unusual presentation of a Meckel's diverticulum: A case report. *Int J Surg Case Rep.* 2015;16:48-51.
10. Elsayes KM, Menias CO, Harvin HJ, et al. Imaging manifestations of Meckel's diverticulum. *AJR Am J Roentgenol.* 2007;189(1):81-8.
11. Zani A, Eaton S, Rees CM, et al. Incidentally detected Meckel diverticulum: to resect or not to resect? *Ann Surg.* 2008;247(2):276-81.
12. Healy JM, Olgun LF, Hittelman AB, et al. Pediatric incidental appendectomy: a systematic review. *Pediatr Surg Int.* 2016;32(4):321-35.