

Epididymo-orchitis Masquerading as Torsion in Scrotal Swelling Case: Radiologist's Dilemma for the Diagnosis?

Bharat Bhushan Sharma^{1*}, Mir Rizwan Aziz², Neeru Kapur², Tanu Singh², Dhiraj Kumar², Natasha Nargotra³ and Rohit Sharma³

¹Professor & HOD, Department of Radio-diagnosis, SGT Medical College, India

²Assistant Professor, Department of Radio-diagnosis, SGT Medical College, India

³Senior Resident, Department of Radio-diagnosis, SGT Medical College, India

*Corresponding author: Sharma BB, Professor & HOD, Department of Radio-diagnosis, SGT Medical College, India, Tel: +919811113557; E-mail: bbhushan986@gmail.com

Received: May 20, 2020; Accepted: May 25, 2020; Published: June 02, 2020

Abstract

Background: Epididymo-orchitis is the inflammation of epididymis leading to testicular involvement. Scrotal abscess is complication of epididymo-orchitis and if this is associated with early torsion then the diagnosing it always poses a challenge for the radiologist. First line of imaging in these cases is always ultrasonography (USG) and color flow imaging (CFI). This shows the similar appearance like many other pathologies and magnetic resonance imaging (MRI) is helpful in differentiating these pathologies.

Case report: We report 32 years old male who reported with the left side scrotal swelling and pain with preceding febrile illness two weeks back. USG and CFI had shown swollen left testis with no flow within it. The peritesticular region and spermatic cord was showing abundant flow. Contrast MRI had revealed no enhancement of the left testis with abundant enhancement of the peritesticular region. The diagnosis of Epididymo-orchitis with testicular infarct / abscess was made. The patient was managed surgically with orchiectomy.

Conclusion: Epididymo-orchitis is usually diagnosed when the increased testicular blood flow is seen in CFI with other features. But with the help of combination of USG, CFI and MRI, the exact underlying condition of epididymo-orchitis leading to early testicular ischemia was diagnosed. MRI showed non enhancement of the left testis along with abscess formation. The case was treated with broad spectrum antibiotics on initial visit followed by orchiectomy once testicular ischemia ensued.

Keywords: *Epididymo-orchitis; Scrotal abscess; USG; CFI; MRI*

1. Introduction

Epididymo-orchitis is inflammation of both the component of scrotal sac including epididymis as well as testis. Isolated orchitis is less common entity. This leads to the serial changes with the passage of time which manifest in the form architectural as well as physiological changes in these two components [1,2]. The incidence is common in less than 2 years and more than 6 years of age. This can cause various complications like testicular ischemia and abscess.

2. Case Report

32 years old male reported to the emergency with the pain and moderate swelling of the scrotal sac. The swelling was progressive in nature for the last two weeks but was without any pain in the beginning (FIG. 1).

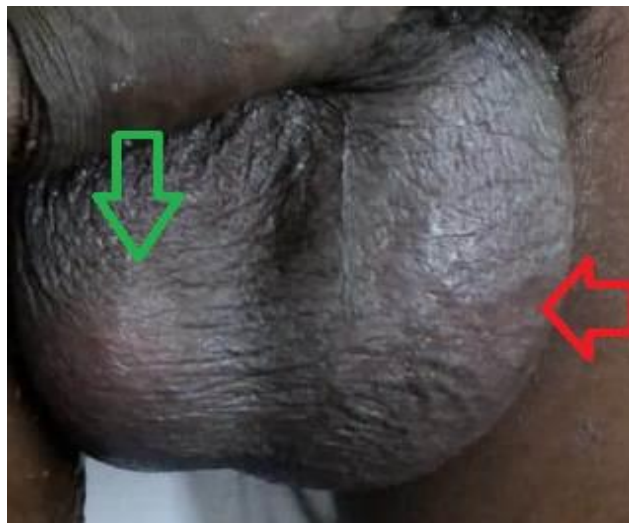


FIG. 1. Photo of scrotal sac. There is obvious swelling and enlargement of left side (red horizontal arrow) with normal size of right side testis (green vertical arrow). The overlying skin is slightly thickened but does not show any ulceration.

He had febrile illness in the beginning and did not take any specialized treatment. There was no previous history of any systemic disease relevant to the present symptomatology. There was no history of mumps or syphilis. On examination he was well built with average physique. Systemic examination was unremarkable. On the examination there was swelling on the left side of the scrotal sac. The overlying skin did not show any change in color or ulceration. On palpation the swelling was soft, tender and there was slight nodularity in the consistency. The left testis was placed slightly in transverse plane. TWIST (testicular workup for ischemia and suspected torsion) was three (total being 7) which was of intermediate type for the management point of view.

Routine investigations were normal except a slight raise in total leukocytic count. Ultrasonography findings revealed the edematous left testis with bulky epididymis. The left testicular volume was increased as compared to the right side. There was mild fluid collection in the left scrotal sac. The scrotal sac wall was thickened. The right testis was normal in appearance with very minimal fluid in the scrotal sac. The spermatic cord on the left side was thick and slightly echogenic with multiple

drop-echo regions (FIG. 2, 3 and 4). Initial Doppler study had revealed increased color flow in left epididymis and cord leading to a diagnosis of left epididymitis with funiculitis.

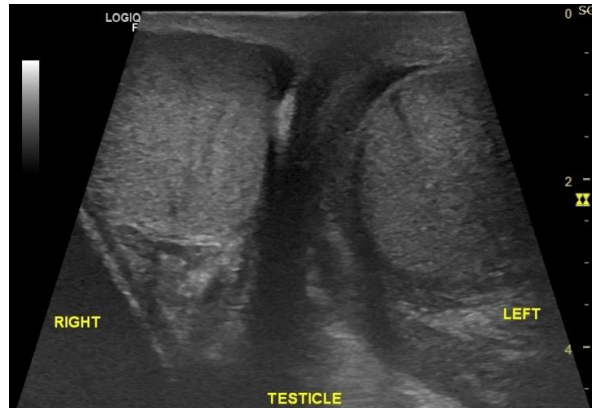


FIG. 2. Ultrasound image of scrotal sac. Both the testes are normal in outline and echo texture. No calcification is seen in any of the testis.

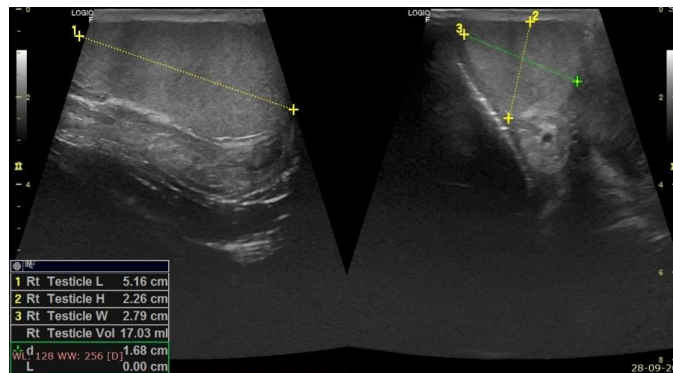


FIG. 3. Ultrasound image of right testis. Horizontal and transverse section show normal echogenicity and volume.

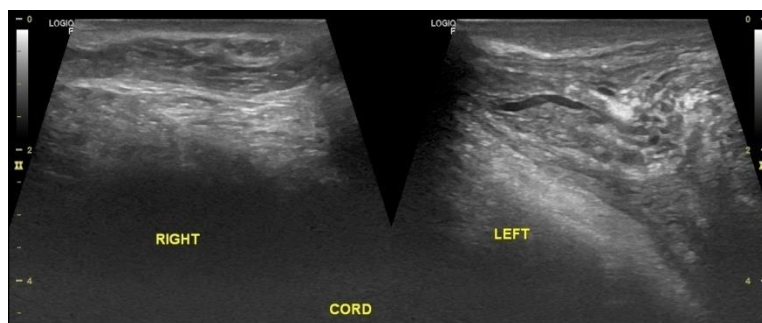


FIG. 4. Spermatic cords on both sides. Right side is normal. Left cord is thickened with increased echogenicity and flow voids.

Color flow imaging performed a few days later had revealed normal flow pattern on right side however there was no flow seen in the left testis. There were multiple arterial channels seen in the spermatic cord region with increased resistive index. Early whirlpool sign was demonstrated. Venous channels were not visualized. Sonographic fountain sign was not seen (FIG. 5, 6, 7, 8 and 9.).

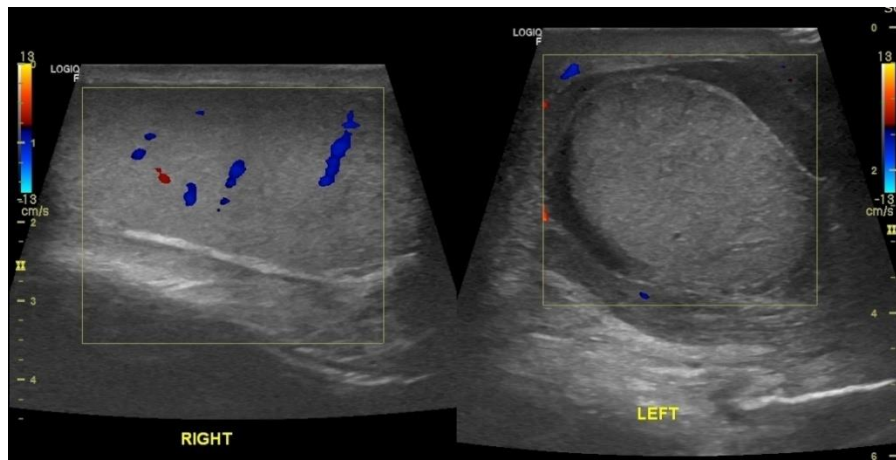


FIG. 5. Color flow imaging. Right testis shows normal intratesticular blood flow but left testis does not show any blood flow. The blood vessels are seen in the peripheral region.

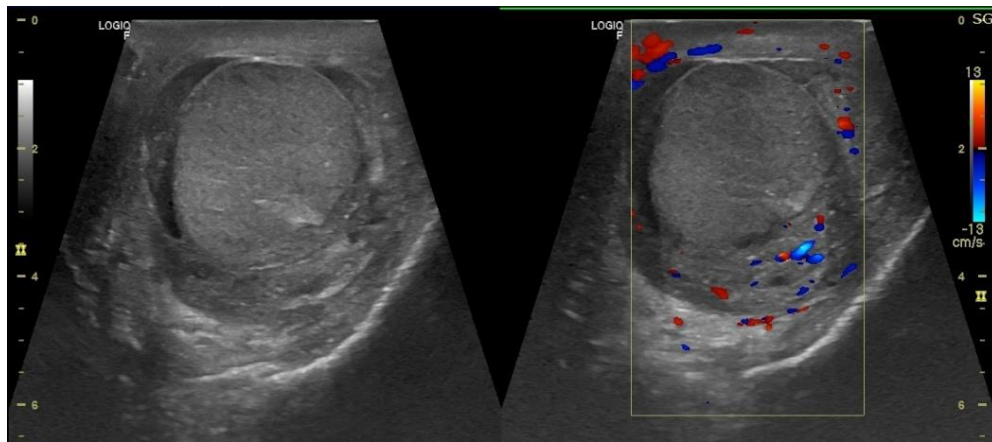


FIG. 6. Ultrasound and color flow images of left testis. Grey scale image on left side and color Doppler on right side. The flow is seen on the peripheral part without any intratesticular flow.

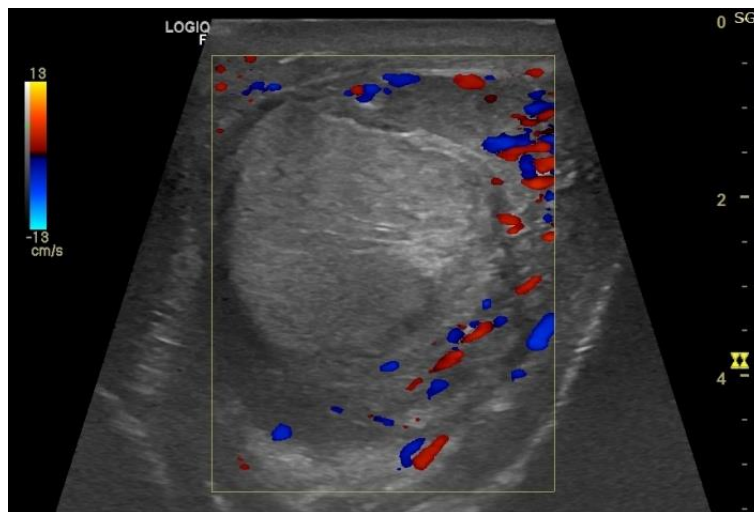


FIG. 7. CFI of left testis in low flow setting. No blood flow seen in the left testis.

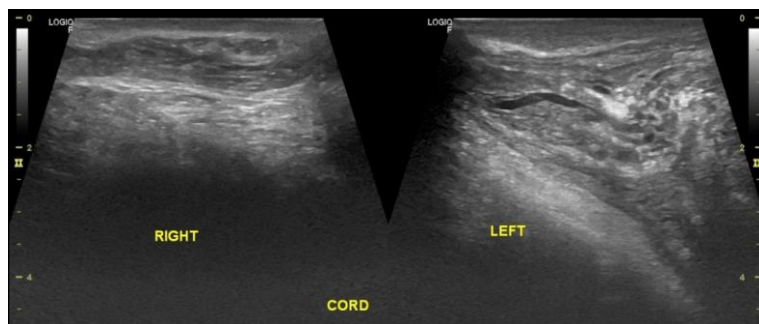


FIG. 8. Spermatic cord grey scale ultrasound images. Right cord shows normal appearance as compared to the left which is thickened and echogenic with flow voids.

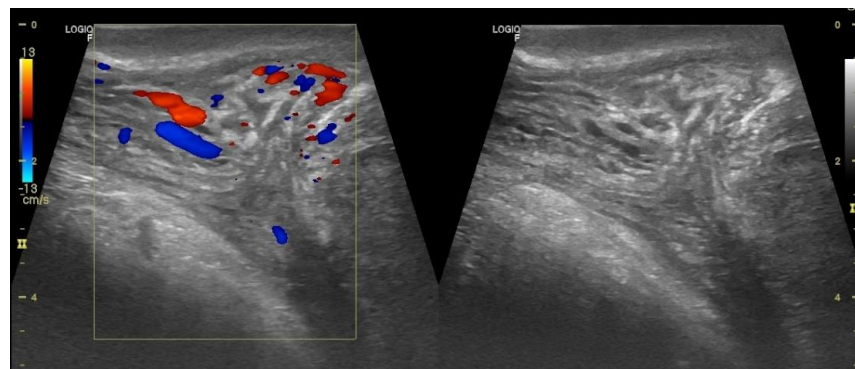


FIG. 9. Left spermatic cord. CFI shows arterial vascularity with decreased venous drainage (left image). Grey scale image shows increased echogenicity with flow voids (right image).

Magnetic resonance imaging was done which revealed non-enhancing left testis with normal signal on T1WI and T2WI and normal enhancement pattern on the right side. DWI was equivocal showing diffusion restriction with decrease ADC (apparent diffusion coefficient) values.

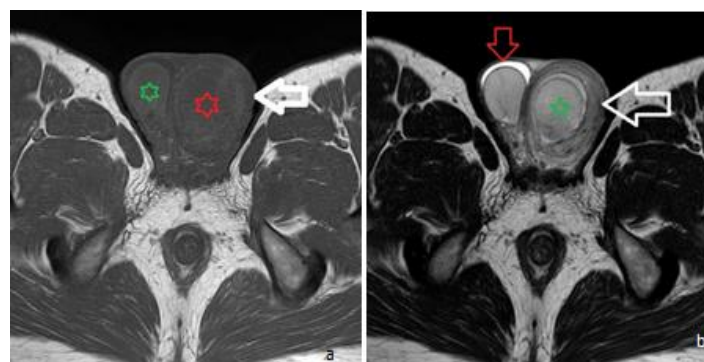


FIG. 10. MRI scrotum axial section. (a) T1W shows normal hypo intensity of both the testes. Rt testis is normal in size (green star) as compared to enlarged left testis (red star). The overlying skin is thickened (white arrow). (b) T2WI shows normal intensity with slight increase in size of the left testis (green star). There is minimal free fluid in right scrotal sac shown as hyper intense crescent (inverted red arrow). Left scrotal skin and wrapping is thickened (white arrow).

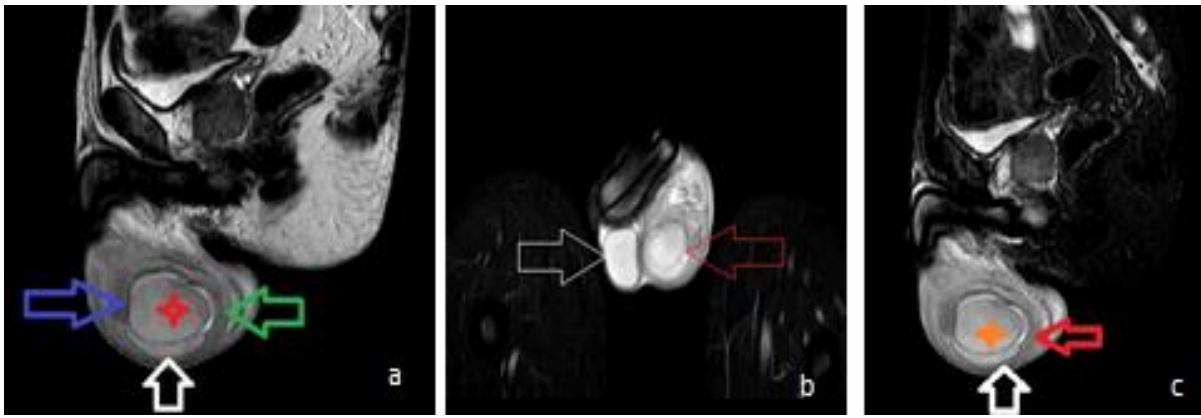


FIG. 11. MRI images contd. (a) T1WI sagittal section of left scrotum shows hypointense left testis (red star) with minimal hydrocele (white arrow) thickened tail (green arrow) and head (blue arrow) of the epididymis. (b) coronal STIR section of the scrotum shows less intense signal from left testis (red arrow) as compared to right testis (white arrow). (c) STIR sagittal section shows hypointense testis (saffron star) with thickened wall (red arrow) and minimal collection (white arrow).

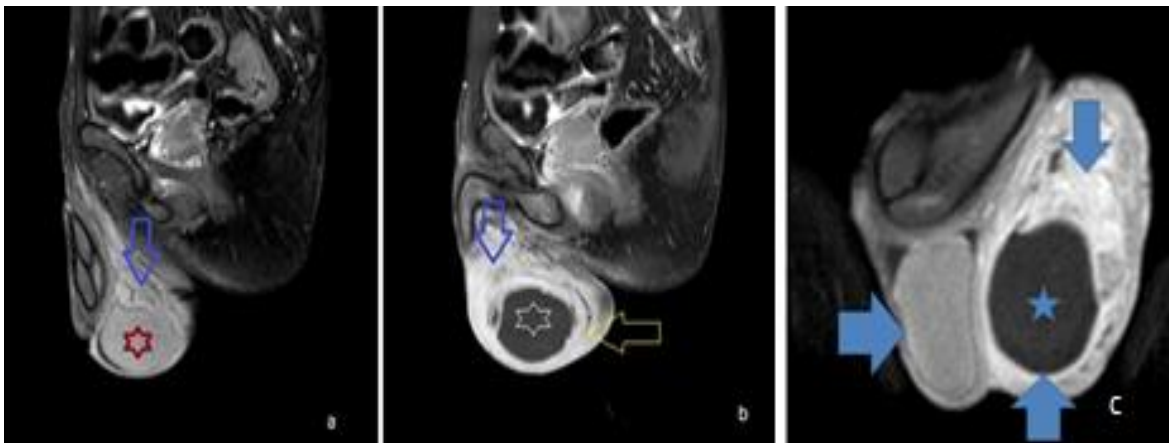


FIG. 12. Post gadolinium enhanced fat suppressed T1WI images of left testis. (a) parasagittal section for the right testis with normal enhancement (red arrow) and normal enhancing right spermatic cord (blue arrow). (b) left parasagittal section of the left testis shows non enhancing left testis (white arrow) with thick enhancing wall (white arrow) with intense enhancement of the peripheral region (blue arrow). (c) coronal section shows the normal enhancing right testis (blue horizontal arrow) and non-enhancing left testis (blue star).

The patient was initially managed conservatively with broad spectrum antibiotics, analgesics, rest and scrotal support. However, after the second Doppler study and MRI raised the possibility of testicular ischemia / abscess decision of left orchietomy was taken and surgery performed. As per the macroscopic findings there were no torsion but partial infarct was noticed in left testis. Histopathological examination confirmed the same diagnosis.

3. Discussion

Epididymis is a tubular structure located on the posterior and superior part of the testis. This is a part of the genitourinary tract that includes the testis, the vas deferens, the prostate, the urethra and the urinary bladder (FIG. 13).

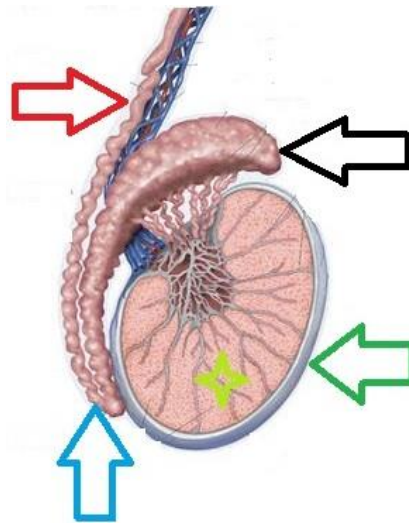


FIG. 13. Diagrammatic representation of testis with vas deferens. Sagittal section showing the core testis (yellow star) with tunica albuginea (green arrow). Vas deferens (red arrow) is seen with tail (blue arrow) and head (black arrow) of epididymis.

The incidence of torsion had been noticed as one among 4000 cases in males younger than 25 years of age. The cases of scrotal pain should be considered as torsion until proved otherwise. The main aim is to salvage the testis by appropriate management. Appendix testis torsion is common in children and the absence of cremasteric reflex is the diagnostic sign of torsion. Blue dot sign is pathognomonic for the pathology. Radionuclear scanning can be performed if there is any doubt in the diagnosis and the same should be performed without any delay [3]. Epididymo-orchitis is result of the ascending infection from the urinary tract. This includes two components as epididymitis and orchitis [4,5]. There are fewer chances for orchitis being present alone. The testicular abscesses are the result of already existing epididymo-orchitis. The pathogens can either be due to sexually or non-sexually transmitted disease. There is great realization required to differentiate between torsion which is encountered as urological emergency.

Spermatic cord swelling and impairment of the blood flow further leads to the complications. Ultrasonography is the imaging modality of the choice as this is non-invasive and easily affordable. This reflects about the altered echogenicity, vascularity, epididymitis, reactive hydrocele; scrotal skin thickening or some evidence of gas within the scrotum. The echogenicity varies from complex mixed structure to the isoechoic nature to the testis [6]. Contrast enhanced ultrasonography (CEUS) and power Doppler ultrasound (PDUS) play additional role in solving the diagnostic dilemma. This can identify the unviable tissue at the earliest. The region is avascular or increased surrounding vascularity. The entity has to be differentiated from testicular cancer, torsion with necrosis and testicular trauma. MR is also very important tool in differentiating the pathologies from the neoplasms. In neoplasms the testicular mass is hypointense with heterogeneity in T2WI sequence. These also show heterogeneous enhancement after contrast enhancement in T1WI sequence [7,8]. The mainstay of the management remains surgical exploration for the restoration of the blood supply to the testis within six hours which is the optimal time frame. Manual detorsion is the mode of management in torsion and the same should be confirmed by color Doppler after the maneuver. Orchiopexy provides the definite treatment after surgical exploration. The surgical management in children for the appendix testis torsion is not much of advantage except the early recovery [9,10]. In some complicated cases surgical

orchietomy is the only management. The functions can return to normal after the management except few cases where atrophy ensues after the treatment [11,12].

4. Conclusion

Epididymo-orchitis and torsion poses a great challenge and dilemma for the radiologist to arrive at a diagnosis. But with the help of USG, CFI and MRI the problem is solved to some extent. The exact underlying condition of early infarct was diagnosed as there was no flow and enhancement in the left testis. The problem becomes easier with MRI as it is a reliable tool in evaluation of scrotal lesions. DWI and ADC values further help in differentiating the benign and malignant lesion which avoids unnecessary surgical procedures.

5. Acknowledgement

We are thankful to Mr. Prashant and Ms. Suzeen Makroo of Faculty of Allied Health Sciences and Mr. Brijesh and Mrs. Anita, data entry operators for providing us the necessary input in the case.

6. Consent of the Patient

The written consent of the patient was taken.

7. Conflict of Interest

We have no conflict of interest to declare

8. Ethical Issue

Nil.

REFERENCES

1. Berman JM, Beidle TR, Kunberger LE, et-al. Sonographic evaluation of acute intrascrotal pathology. *AJR Am J Roentgenol.* 1996;166(4):857-61.
2. Trojian TH, Lishank TS, Heiman D. Epididymitis and orchitis an overview. *Am Fam Physician.* 2009;79(7):583-7.
3. Ringdahl E, Teague L. Testicular torsion. *Am Fam Physician.* 2006;74(10):1739-43.
4. McConaghy JR, Panchal B. Epididymitis: An Overview. *Am Fam Physician.* 2016;94(9):723-6.
5. Yamamichi F, Shigemura K, Arakawa S, et al. What are the differences between older and younger patients with epididymitis? *Investig Clin Urol.* 2017;58(3):205-9.
6. Serra AD, Hricak H, Coakley FV, et al. Inconclusive clinical and ultrasound evaluation of the scrotum: impact on magnetic resonance imaging on patient management and cost. *Urology.* 1998;51(6):1018-21.
7. Thakur A, Buchmiller T, Hiyama D, et al. Scrotal abscess following appendectomy. *Pediatr Surg Int.* 2001;17(7):569-71.

8. Tsili AC, Argyropoulou MI, Giannakis D, et al. Magnetic resonance imaging in the characterization and local staging of testicular neoplasms. *AJR Am J Roentgenol.* 2010;194(3):682-9.
9. Aso C, Enriquez G, Fite M, et al. Grey-scale and color Doppler sonography of scrotal disorders in children: an update. *Radiographics.* 25(5):1197-214.
10. Woodward PJ, Schwab CM, Sesterhenn IA. From the archives of the AFPIP: extratesticular scrotal masses: radiological-pathologic correlation. *Radiographics.* 2003;23(1):215-40.
11. Smith RP, Tracy CR, Kavoussi PK, et al. The impact of color Doppler ultrasound on treatment patterns of epididymitis in a university-based healthcare system. *Indian J Urol.* 2013;29(1):22-6.
12. Street EJ, Justice ED, Kopa Z, et al. The 2016 European guidelines on the management of Epididymo-orchitis. *Int J STD AIDS.* 2017;28(8):744-9.