

## The Evolution of CT Imaging of 2019 Novel Corona Virus Pneumonia

Yifan Wang<sup>1#</sup>, Xingcang Tian<sup>1#</sup>, Pan Zhou<sup>2</sup>, He Wang<sup>3</sup>, Shuping Meng<sup>1</sup>, Wenling Li<sup>1</sup> and Li Zhu<sup>1\*</sup>

<sup>1</sup>Department of Radiology, General Hospital of Ningxia Medical University, Yinchuan, Ningxia, China

<sup>2</sup>Department of Radiology, the fourth people's Hospital of Ningxia, Yinchuan, Ningxia, China

<sup>3</sup>Department of Radiology, the first people's Hospital of Yinchuan, Yinchuan, Ningxia, China

<sup>#</sup>These two authors contributed equally to this work and should be considered co-first authors

\***Corresponding author:** Zhu L, Department of Radiology, General Hospital of Ningxia Medical University, 804 Shengli Street, Xingqing District, Yinchuan 750004, Ningxia, China, Tel: +86- 13995172918; E-mail: [zhuli72@163.com](mailto:zhuli72@163.com)

**Received:** July 27, 2020; **Accepted:** August 05, 2020; **Published:** August 13, 2020

### 1. Case Presentation

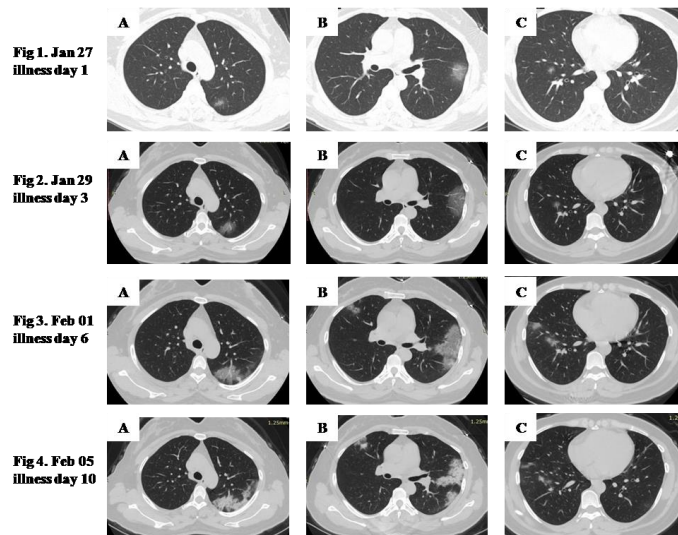
A 38-year-old woman was one of close contacts with a patient confirmed 2019 novel coronavirus in a family cluster for 7 days [1]. She presented with a 3-day history of intermittent fever, slight cough.

Her body temperature was elevated to 38.2°C. Coarse breath sounds were noted in both lungs on auscultation. Laboratory results showed white blood cell count was  $3.84 \times 10^9/L$ , neutrophils were 54.6% and lymphocytes were 36%. The level of C-reactive protein increased to 10.69 mg/L (normal range, 0-6 mg/L) and erythrocyte sedimentation rate was 3 mm/h (normal range, 0-20 mm/h).

Prothrombin time was 9.9s (normal range, 10-14s) and D-dimer was 1 ug/mL (normal range, 0-1 ug/mL). Unenhanced chest computed tomography (CT) showed multiple patchy ground-glass opacities in both lungs (FIG. 1-4). The real-time reverse transcriptase polymerase chain reaction (RT-PCR) of the patient's oropharyngeal swab were positive for 2019 novel coronavirus (nCoV) nucleic acid.

Based on the epidemiological characteristics, clinical manifestations, CT findings and laboratory tests, the diagnosis of 2019-nCoV pneumonia was confirmed [2,3].

The patient has been given interferon inhalation and lopinavir/ritonavir, supplemented with Chinese medicine.



**FIG. 1. Image shows multiple patchy ground-glass opacities in both lungs. FIG 2-4. Follow-up images show progressive ground-glass opacities and consolidations in both lungs. The range of lesions expanded, and the density of lesions increased. The lesions in the lingula and posterior segment of the left upper lobe (FIG. 3) are still dominated by ground-glass opacities, and thickened small pulmonary vessel can be seen (FIG. 2A, 3A and 1B, 3B). Fine mesh sign can be seen due to thickening of the interlobular septa (FIG. 3B). Meanwhile, air bronchogram can be seen in the anterior segment of the right upper lobe (FIG. 3B) and lingula of the left upper lobe (FIG. 4B). With the progression of 2019 novel coronavirus pneumonia, the density of the lesions changed from ground-glass opacities to consolidations, while the boundaries of the lesions were clear (FIG. 3A, 4A and FIG. 3B, 4B), which is different from the blurry boundary of community-acquired pneumonia.**

#### REFERENCES

1. Li Q, Guan X, Wu P. Early transmission dynamics in Wuhan, China, of Novel coronavirus-infected pneumonia. *N Engl J Med.* 2020;382:1199-1207.
2. Huang C, Wang Y, Li X. Clinical features of patients infected with 2019 novel Coronavirus in Wuhan, China. *Lancet.* 2020;395(10223):497-506.
3. Chen N, Zhou M, Dong X. Epidemiological and clinical characteristics of 99 cases of 2019 novel coronavirus pneumonia in Wuhan, China: a descriptive study. *Lancet.* 2020;395(10223):507-13.