

## Lunotriquetral Coalition: Report of Two Different Cases

Mohammed Ali F Al Bayati<sup>1\*</sup>, Thena J Al Khishali<sup>2</sup>, Mohanad MA Al Bayati<sup>3</sup> and Hameed BM<sup>4</sup>

<sup>1</sup>MD, FRCS Ed. Al Wasity Teaching Hospital, Baghdad, Iraq

<sup>2</sup>DGO, M.Sc., Ph. D, Dentistry College, Uruk University, Baghdad, Iraq

<sup>3</sup>MD, Orthopedic specialist, Skaraborg Hospital, Skovde, Sweden

<sup>4</sup>FICMS (Fellow of Iraqi Commission for Medical Specialization), Orthopedic specialist Al - Wasity Teaching Hospital, Baghdad, Iraq

\*Corresponding author: Al Bayati MAF, FRCS Ed, Emeritus consultant, Orthopedic surgeon, Al Wasity Teaching Hospital, Sanaa St. 1, Karada, Po Box; 38032 Rusafa - Baghdad, Iraq, Tel: 009647901806170; E-mail: [mabayatti@yahoo.com](mailto:mabayatti@yahoo.com)

Received: November 14, 2020; Accepted: December 01, 2020; Published: December 08, 2020

### Abstract

Lunotriquetral coalition (LTC) is most common of other coalitions in the hand. It is a rare condition, more frequent in females, and mostly in West Africans. LTC is an autosomal dominant condition. It can be complete or partial. Minnaar classified it into four types, and Burnett suggested two types. LTC is largely asymptomatic and discovered incidentally on radiograph. However, incomplete fusion can be symptomatic due to arthritis of the abnormal articulation. It presents as moderate pain in the wrist, weakness, decrease of grip strength. Most of cases can be treated conservatively, few cases with incomplete fusion needs surgical arthrodesis of the two bones. Here we present two different cases of LTC and their management.

**Keywords:** *Lunate; Triquetral; Coalition; Arthrodesis*

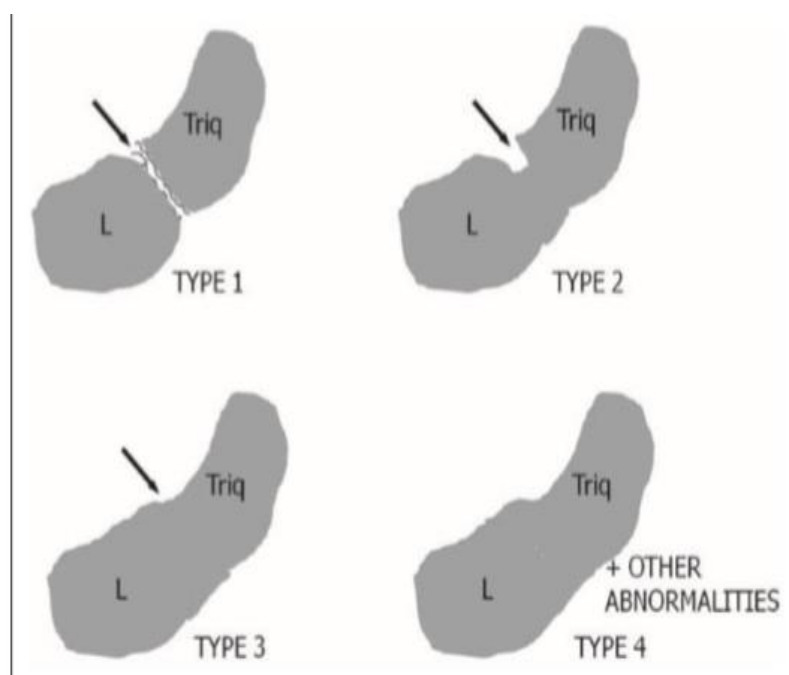
### 1. Introduction

Lunotriquetral coalition (LTC) is fusion of the lunate and triquetral bones of the carpus. LTC is most common accounting 90%, of all coalitions in the hand frequently bilateral, in unilateral cases mostly on the left side [1,2]. It can be between any carpal or metacarpal bones, but mostly in one row on the ulnar side. Incidence is 0.1% in Caucasian population, more in females with 2: 1 ratio. Incidence is higher in Africans, mostly in West African tribes up to 9%, 1 [3-5]. It is hereditary, dominant, autosomal linked condition of failure of cavitation of wrist cartilage, occur in the 4-8 months of gestational period. Coalition can be fibrous, cartilaginous, or osseous, complete, or partial. It appears on radiograph in early adulthood, from 6-14 years, with ossification of carpal bones.

Carpal coalition is largely asymptomatic and discovered incidentally by radiograph of the wrist for other conditions. Rarely does it produce symptoms of wrist pain and weakness, mostly in incomplete pseudo arthrosis between two carpal bones [3,4,6,7].

The fibro cartilaginous coalitions are usually incomplete and can be symptomatic when the wrist is exposed to extra strains or trauma [3]. Pain in the wrist due to the accompanying soft tissue inflammation, and /or degenerative arthritis, can be the presenting cause for seeking remedy [1,8,9]. LTC can be part of other syndromic conditions [1,2].

Minnaar de Villiers in 1952, suggested a classification of four types of coalition (FIG. 1) [5]. Burnette S. in 2011, proposed a simpler classification, into Osseous, and Non osseous coalition [6]. We think Burnette classification is more consistent with the clinical presentation of patients.



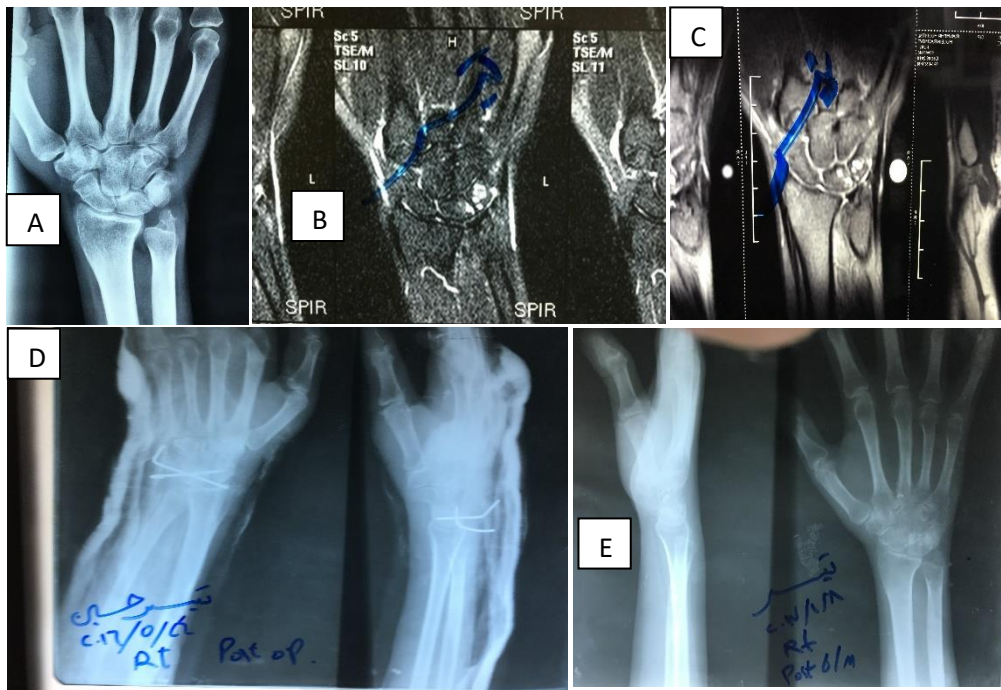
**FIG. 1. Minnaar types 1 to 4. Schematic view. Type 1: narrowed LTJ with irregular sclerotic margins (arrow). Type 2: incomplete osseous fusion with (small) mostly distal remnant of joint space (arrow). Type 3: complete osseous fusion between the lunate and triquetral bone (arrow). Type 4: = Type 3 with other carpal congenital bony abnormalities [5].**

MRI imaging is most useful in differentiating the type of coalition and presence of bone marrow edema, cystic changes, and/or inflammatory arthritis in Pseudarthrosis (type I Minnaar), or (non-osseous type) of Burnette classification. This helps to decide the type of treatment for individual case [1,4,7-9].

## 2. Case 1

A 26-year mother of two, right-handed, with body mass index (BMI) of 22, referred to consultation hand clinic, complaining of chronic pain in the left wrist for 18 months. She was treated efficiently by conservative measures, namely non-steroidal anti-inflammatory medications, and variable wrist splints. From history, the pain was chronic, intermittent, and progressive in

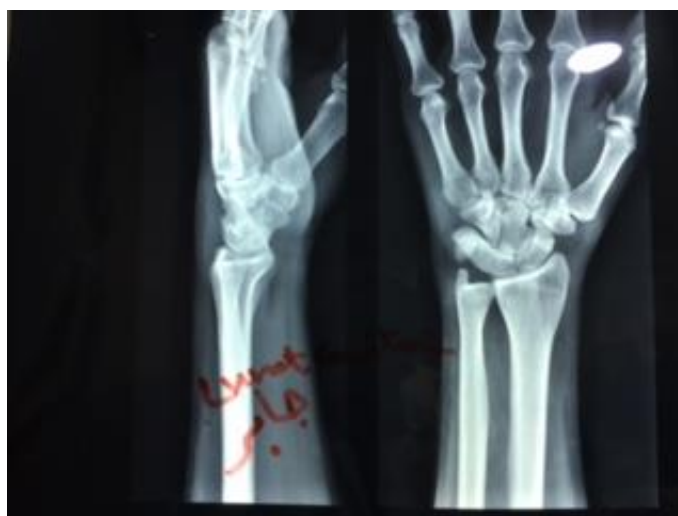nature. It was provoked by work exertion. The pain was mostly on the ulnar side of the wrist and hand, radiating to the hypothenar and little finger area, associated with abnormal sensations at the ulnar nerve dermatome. On physical examination, the left wrist was slightly tender on the ulnar side and distal radio-ulnar joint. Pain was produced by mainly ulnar deviation, dorsiflexion of the wrist and moving the distal ulna. There was mild wasting in the hand muscles, with normal looking skin. Plain radiograph of the left wrist showed decrease of the joint space and mild sclerosis at the luno-triquetral joint (FIG. 2). General blood examination, ESR (erythrocyte sedimentation rate) and CRP (C - reactive protein), revealed normal values. Her nerve conduction studies were normal. A magnetic resonant imaging (MRI) ordered, and it revealed marked changes of degenerative arthritis at the luno-triquetral joint, Minnaar Type 1. The diagnosis of inflammatory degenerative arthritis of LTC was made, and we performed arthrodesis of the joint with temporary internal fixation with 2 K wires and a short gypsum splint for 6 weeks. Early post-operative follows up was uneventful, the clinical condition improved to a great extent. Her 6 months follow up radiograph showed complete arthrodesis of the LTC (FIG. 2). After 30 months post-operation, the women was free of pain, have full range of movement at her left wrist with full satisfaction.



**FIG. 2. Case 1: 26-year women, presented with chronic Lt. Wrist pain on ulnar side, (A), plain radiograph LTC decreased joint space. (B & C), MRI showing fluid & cystic changes at LTJ, LTC Minnaar Type 1. (D), LTJ arthrodesis. (E), 6 M post op. successful fusion, pain relieved.**

### 3. Case 2

A 32-year-old police officer, presented to the hand clinic, complaining of pain in the left wrist for ten days duration. There was no history of direct trauma, apart from daily exertion of force duties and contact sport. On physical examination there was no abnormal signs, no tender spots and range of movement slightly decreased. Plain radiograph of the left wrist revealed complete luno triquetral fusion, Minnaar Type 3, (FIG. 3). The patients reassured, and prescription of analgesia and advised to decrease his violent activities. Seen after three weeks, he was free of pain and back to his usual daily activities.



**FIG. 3. Case 2: 32-year old man presented with pain in Lt. wrist for short duration. Plain radiograph Showing complete LTC, Minnaar type 3, treated successfully by conservative methods.**

#### **4. Discussion**

LTC is a dominant autosomal trait known for long time. It is rare condition, with incidence of 0.1% in general population. Most common in Africans. More frequent in woman. Usually bilateral, when unilateral more on the left side [1-5]. The two cases presented here are, man and women, with unilateral anomaly on the left side. This goes with the published information. LTC is most common in Black Africans up to 9% [1,2], however, the two cases presented were white Caucasians.

LTC is largely asymptomatic discovered on radiographs, yet it can be a real cause of wrist pain especially in incomplete fibrocartilaginous syndesmoses, that can lead to degenerative arthritis [5,6,7]. In case 1, where the women had Type 1 Minnaar coalition, she had genuine persistent pain, which was only relieved by surgical arthrodesis of the luno- triquetral joint. The man in case 2, had complete fused coalition, type 3 Minnaar, and he was cured successfully by conservative treatment. This goes with all previous publications [1-3,7].

MRI is a good tool to diagnose LTC, and is vital to detect the exact type, and the pathological changes in the surrounding cartilage and other soft tissues of the wrist [2].

The MRI solved the cause of the chronic pain in case 1, which showed all signs of degenerative arthritis; it showed bone edema, subchondral cystic changes, and fluids in the synovial space. All because of the non- osseous, incomplete coalition. This was in consistent with most published work. In case 2, plain radiograph was enough to show complete osseous coalition which needed only conservative treatment.

In conclusion, LTC is a rare condition, mostly asymptomatic. It is a congenital autosomal dominant trait mostly bilateral discovered by imaging studies of the wrist. It can be complete osseous, or incomplete fibro- cartilaginous, where it can be symptomatic and necessitate operative treatment. LTC should be in the list of differential diagnosis of wrist pain and needs more awareness by practitioners and orthopedic surgeons.

## 5. Disclosures

There is no conflict of interest of all the authors, related to this study. Consent were taken from patients to use their information in the study with preservation of privacy.

## REFERENCES

1. Mbaba AN, Ogolodom MP, Wekhe C, et al. Lunotriquetral Coalition: An infrequent cause of wrist pain - A case Report. *Health Science J.* 2019;13(4):667.
2. Mespreuve M, Vanhoenacker F, Verstraete K. Lunotriquetral coalition, a normal variant that may rarely cause ulnar sided wrist pain. *J Belg Soc Radiol.* 2015;98(2):72-78.
3. Lotter O, Sthal S, Luz O, et al. Bilateral paradoxically symptomatic Lunotriquetral coalition: a case report. *Eplasty.* 2010;10:e47.
4. Simmons BP, McKenzie WD. Symptomatic Carpal Coalition. *J hand Surg Am.* 1985;10(2):190-3.
5. Minnaar ABD. Congenital fusion of lunate and triquetral bones in the South African Bantu. *J Bone Joint Surg Br.* 1952;34-B(1):45-8.
6. Burnett SE. Hamate- Pisiform coalition: Morphology, clinical significance, and a simplified classification scheme for carpal coalition. *Clin Anat.* 2011;24(2):188-96.
7. Ali R, Khan F, Saeed S, et al. Lunotriquetral coalition: An Unusual cause of wrist pain. *Cureus.* 2019;11(9):e5704.
8. Gross SC, Watson HK, Strickland JW, et al. Triquetral-Lunate arthritis secondary to synostosis. *J Hand Surg Am.* 1989;14(1):95-102.
9. Ozyurek S, Guler F, Canbora K, et al. Asymptomatic Lunotriquetral Coalition. An incidental radiographic finding. *BMJ Case Rep.* 2013;2013:bcr2013009429.