

A Not So Transient “Transient Osteoporosis” of the Spine in Pregnancy

Partap A* and Seepaul T

Department of Orthopedics, San Fernando General Hospital, San Fernando, Trinidad

*Corresponding author: Partap A, Department of Orthopedics, : San Fernando General Hospital, Independence Avenue, San Fernando, Trinidad, Tel: 1-868-225-4325; E-mail: amandapartap@gmail.com

Received: August 01, 2021; Accepted: August 12, 2021; Published: August 20, 2021

Abstract

Introduction: Transient Osteoporosis of Pregnancy is a rare potential complication of pregnancy which unexpectedly affects young, healthy women with a previously uneventful pregnancy. The diagnosis is usually one of exclusion with its true incidence being unknown because of its self-limiting nature in most cases.

Case: A 32-year-old primigravida began having lower back pain at 30 weeks gestation and underwent a caesarean section at 38 weeks gestation. Post-delivery her symptoms deteriorated, and she had a magnetic resonance imaging (MRI) of her spine. The findings of the MRI confirmed osteoporosis induced vertebral compression fractures during the post-partum period. Intravenous ibandronic acid was used for treatment for a period of three (3) years with annual Dual Emission X-ray Absorptiometry (DEXA) scan to evaluate progression. The patient’s symptoms resolved by six (6) months post diagnosis highlighting the transient nature of this condition. The serial DEXA scans however revealed a less than transient resolution of her bone mineral density over the three-year period.

Conclusion: The length of time required for treatment is still controversial since the time taken for bone mineral density levels to return to normal limits is highly variable as was demonstrated by the case presented. However, the treatment protocol adopted for this patient has proven to be a safe and effective regime which can be implemented as a viable treatment option by clinicians.

Keywords: *Osteoporosis; Pregnancy; Bisphosphonate; Vertebral fractures; Case report*

1. Introduction

Transient Osteoporosis of Pregnancy was first described in 1958 by Curtiss and Kincaid after evaluation of three pregnant patients with painful hips during their third trimester [1]. It is a rare potential complication of pregnancy which unexpectedly affects young, healthy women with a previously uneventful pregnancy [2]. The most commonly affected area is the femoral neck, but it can also involve the shoulder, knee, and ankle [3]. The diagnosis is one of exclusion with the commonest differential diagnoses being a joint infection, rheumatoid arthritis, avascular necrosis of femoral head, pigmented villonodular synovitis,

Citation: Partap A, Seepaul T. A Not So Transient “Transient Osteoporosis” of the Spine in Pregnancy. Clin Case Rep Open Access. 2021;4(3):192.

©2021 Yumed Text.

reflex sympathetic dystrophy and idiopathic osteochondromatosis. This patient described underwent a three year follow up with consecutive annual Dual Emission X- ray Absorptiometry (DEXA) scan which highlights the lack of the transient nature of this condition regarding objective improvements in the bone mineral density scores. However, in terms of the subjective resolution of symptoms the condition can indeed be considered a transient one with symptoms resolving after six (6) months.

2. Case Report

A 32-year-old primigravida presented with lower back pain at 30 weeks gestation. She endured these pains until the 38th week of gestation when she underwent a caesarean section. Post-partum she continued to have lower back pain with features suggestive of sciatica and had a spine MRI three (3) days later. The report stated all was normal with only slight annular disc bulges. Subsequently the patient was not seen for approximately two months but returned with an acute migration of the pain to the thoracic region. There was no history of any trauma or heavy lifting. She reported a regular menstrual cycle with no osteoporosis-related risk factors such as family history, smoking and prevalent fractures. Additionally, there was no secondary cause of osteoporosis.

The physical examination showed her height was 59 inches with a weight of 116 lbs and a body mass index of 23. She was also tender over the lower thoracic region with an apparent kyphosis. There was no associated motor or sensory neurological deficit. A plain radiograph revealed osteopenia with sequential wedge compression fractures of vertebra T9 through T12. FIG. 1 Further investigations to determine a potential secondary cause of osteoporosis included serum calcium, alkaline phosphatase, phosphate, thyroid function, parathyroid hormone, vitamin D, FSH, LH, progesterone and estradiol levels as well as renal and liver function tests which were all normal.

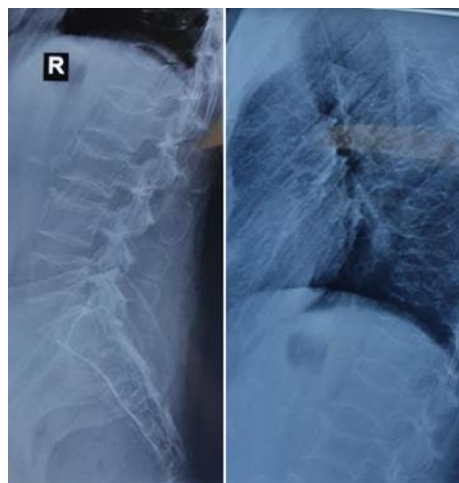

FIG. 1. Radiographs showing wedge compression fractures from T9 through T12.

Her DEXA scan was done three (3) months post-partum and showed a Z score of -3.7 which confirmed the diagnosis of osteoporosis. A thoracolumbosacral orthosis (TLSO) brace was recommended and intravenous ibandronate (Bonviva) was commenced at a dose of 3mg every three (3) months. DEXA scans were subsequently repeated at 6 months, and annually for three (3) years post diagnosis as a means of monitoring her improvement. Significant improvement regarding her pain level was noted with six (6) months of commencing treatment with a small but definite improvement in her bone mineral of 9.9% with a Z score of -3.2. FIG. 2 shows the trend of her T and Z scores during the treatment period.

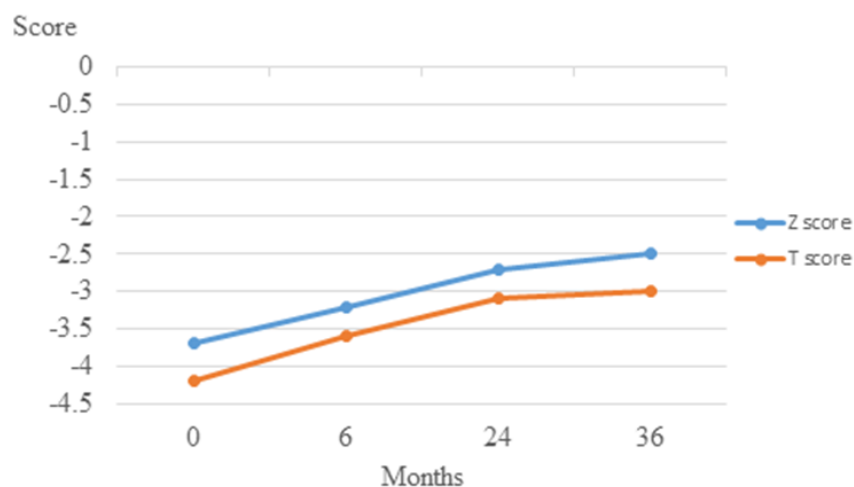


FIG. 2. Changes in T and Z scores using the DEXA method over a period of three years post-partum.

The paucity of information in the literature regarding the management as well as the slow return to normal of her bone density lead to the decision to continue treatment for three years. The patient by this time had resumed her normal active healthy lifestyle and despite not making a full quantitative recovery the ibandronate was stopped. Blood investigations as outlined previously were repeated and remained within normal limits. The patient at two years after ceasing pharmacological treatment continued to be asymptomatic. Informed consent was obtained from the patient for the medical use of her case details.

3. Discussion

The true incidence of pregnancy-associated transient osteoporosis is unknown since it is underdiagnosed as the natural course is self-limiting with symptoms typically improving over 6-12 months [4]. The characteristic clinical scenario is a complaint of chronic back pain or the sudden onset of sharp back pain and loss of height due to vertebral compression fractures [5]. Researchers are debating the etiology of this syndrome which is still unknown with some suggesting the involvement of hereditary factors in its pathogenesis [6]. Furthermore, transient osteoporosis of the spine is sometimes described as a separate condition from transient osteoporosis of the hips with these patients typically presenting post-partum with vertebral fractures as in the case presented [7].

The diagnosis therefore during pregnancy is difficult with many of the diagnostic techniques not being recommended for pregnant women. In addition radiographs are usually quite challenging because they are unable to quantify bone density [8]. However, the term "*osteopenia*" has been used to qualitatively describe an increase in radiolucency of the bone which suggests a low mineral content. It is usually detected incidentally on X-ray examination with at least thirty percent (30%) of bone mineral content being lost to give this characteristic feature.

Examination of the patient's bone mineral density (BMD) is used to confirm the diagnosis. Bone densitometry can be determined by utilising techniques such as the Quantitative Computed Tomography (QCT) of the spine, which uses low dose radiation to image the vertebrae to measure its mineral content and the DEXA scan which images the spine and hip [9]. The DEXA scan is not universally recommended during pregnancy as it carries a risk of radiation exposure to the fetus. Magnetic

Resonance Imaging (MRI) is therefore the preferred diagnostic tool in pregnant patients since it does not expose the patient to ionizing radiation [3].

The characteristic MRI findings include a low signal intensity of the bone marrow on T1-weighted spin echo images and high signal intensity on T2-weighted images. The presence of normal bone marrow signal intensity of the vertebral body, retropulsion of posterior bone fragment, and multiple compression fractures are also features which may be seen [10]. MRI has a high sensitivity (100%), specificity (93%), and accuracy (95%) in differentiating between acute osteoporotic compression fractures and fractures as a result of metastatic disease [10]. It has more recently been utilised as a tool to evaluate bone density but this requires the use of high resolution MRI [8]. However, this was not the case with this patient since her MRI scan showed no evidence of a low bone mineral density when performed at the onset of her symptoms.

The gold standard for diagnosing osteoporosis is the DEXA scan. The International Society of Clinical Densitometry (ISCD) prefers that Z-scores be used in premenopausal women and in men <50 years old in contrast to the T scores used in postmenopausal women. A Z-score of < -2.0 in these populations indicates a “*low bone density for age.*” The diagnosis of osteoporosis should not be based solely on the BMD scores in these younger adults as there is a lack of longitudinal data relating BMD to fracture risk with younger individuals having a much lower risk for fracture [11]. In these patients, a diagnosis of osteoporosis should be considered if risk factors for bone loss and fractures as well as a history of fragility fractures are present [11]. The patient’s diagnosis was made in accordance with this recommendation since she presented with vertebral fractures and a low Z score.

It is imperative to prevent vertebral fractures as well as increase the patient’s BMD and resistance to fractures when treating osteoporosis in pregnancy or postpartum [5]. Additionally, patients with compression fracture as a result of pregnancy-associated osteoporosis have a 33% risk of developing secondary fractures [12]. The index patient presented with thoracic compression fractures and could not benefit from preventative therapy measures such as bed rest, corset application, calcium, and vitamin D supplementation as well as weaning from breastfeeding [13]. Furthermore, despite not receiving calcium and vitamin D supplementation during her pregnancy period her laboratory reports confirmed no deficiency in either supplement. However, she did cease breastfeeding a few weeks postpartum. The condition generally resolves spontaneously and without any pharmacological intervention [13-15].

Bisphosphonate therapy has been reported in the literature to hasten the recovery period [2]. The use of bisphosphonates is widely accepted for the treatment of osteoporosis in the postmenopausal patient. However, their use during pregnancy remains controversial since it carries a risk of crossing the placenta and may affect fetal serum calcium levels and growth [4,16]. Bisphosphonates are known to be stored in the bone matrix for numerous years and its effect on the fetus in subsequent pregnancies is unclear. Munns et al presented two cases of intravenous bisphosphonate therapy use for five (5) years before conception and demonstrated no negative effects to both mother and child [17]. There have been reports of post-partum treatment of pregnancy-associated osteoporosis with antiresorptive agents like bisphosphonates with improvement in both symptoms as well as BMD [13]. Based on this data the “*off label usage*” of oral and intravenous bisphosphonates have gained popularity in the treatment of this condition in the postpartum patient.

In rare instances, there may be resistance to the beneficial effects of bisphosphonates on BMD. Teriparatide (1,34 parathyroid hormone) has been shown to yield satisfactory results when utilized in these patients with reported improvement of bone density as well as no further occurrence of vertebral fractures [18]. The half-life of teriparatide is an hour, which is much shorter than that of bisphosphonates therefore making it safe for fertile women and a more "*biologic*" alternative for treating pregnancy-associated osteoporosis [19].

The disorder while self-limiting remains unpredictable in terms of its time to resolution. The resolution of symptoms from early as one month postpartum has been recorded in the literature [3]. A defined period for the duration of pharmacological therapy has not been described and most cases in the literature continued treatment until the patient was asymptomatic with no progression of the disease [3,5]. It was decided to follow up the patient with serial DEXA scans to aid in the guidance of therapy. The failure of bone mineral density to return to normal has been previously documented by authors who have followed treatment regimens similar to those in the local setting [20].

The decision to cease intravenous ibandronate treatment was based on a significant improvement of her BMD with complete resolution of her symptoms and no further progression of her fragility fractures. This case highlights that despite the return to a normal BMD level over a three-year period of treatment a significant improvement can be expected in patients undergoing bisphosphonate therapy. The paucity of data to recommend an appropriate guideline for management still exists but we believe that our approach can be safely used as a guide to physicians when managing this condition. The serial DEXA scans revealed that only after three years of treatment a significant improvement was demonstrated thereby supporting our believe that a three-year period of treatment should be undertaken with these patients. The serial review of this patient's clinical sequelae has also shown that a return to a normal bone mineral density should not be considered a pre-requisite for the resolution of symptoms in these cases as both entities appear to occur at different periods of the treatment timeline.

4. Conclusion

The diagnosis of transient osteoporosis of pregnancy relies on a high level of clinical suspicion. In most cases the diagnosis is only evident during the postpartum period despite the onset of symptoms during the third trimester of pregnancy. The use of intravenous ibandronate provides a suitable alternative to oral bisphosphonates, especially in non-compliant patients. The disease is believed to be self-limiting with resolution of symptoms occurring within a few months postpartum as was seen in this case. The resolution of bone mineral density levels, however, appears to be less than a transient process making the determination of an appropriate treatment period a controversial issue in the literature.

5. Conflict of Interest

The Authors declare that there is no conflict of interest and no funding was received.

REFERENCES

1. Curtiss PH, Kincaid WE. Transitory demineralization of the hip in pregnancy. A report of three cases. *J Bone Joint Surg Am.* 1959;41-A:1327-33.
2. Maliha G, Morgan J, Vrahas M. Transient osteoporosis of pregnancy. *Injury.* 2012;43(8):1237-41.

3. Pallavi P, Padma S, Vanitha Anna Selvi D. Transient osteoporosis of hip and lumbar spine in pregnancy. *J Obstet Gynaecol India*. 2012;62(Suppl 1):8-9.
4. Shenker NG, Shaikh MF, Jawad ASM. Rare disease Transient osteoporosis associated with pregnancy: use of bisphosphonate in treating a lactating mother. *BMJ Case Rep*. 2010;2010:bcr0720092112.
5. Nakamura Y, Kamimura M, Ikegami S, et al. A case series of pregnancy and lactation associated osteoporosis and a review of the literature. *Ther Clin Risk Manag*. [Internet]. 2015;11:1361-5.
6. Dunne F, Walters B, Marshall T, et al. Pregnancy associated osteoporosis. *Clin Endocrinol (Oxf)*. 1993;39(4):487-90.
7. Blanch J, Pacifici R, Chines A. Pregnancy-Associated Osteoporosis: Report of Two Cases with Long-Term Bone Density Follow-Up. *Rheumatology*. 1994;33(3):269-72.
8. Link TM. Musculoskeletal Radiology / Radiologies musculo-squelettique Radiology of Osteoporosis. *Can Assoc Radiol J*. 2016;67(1):28-40.
9. Pentyla S, Rahman A, Mysore P, et al. Osteoporosis associated with Pregnancy. *Arch Med*. 2015;7(3).
10. Jung H-S, Jee W-H, McCauley TR, et al. Discrimination of Metastatic from Acute Osteoporotic Compression Spinal Fractures with MR Imaging 1. *RadioGraphics*. 2003;23(1):179-87.
11. Cohen A, Shane E. Evaluation and Management of the Premenopausal Woman with Low BMD. *Curr Osteoporos Rep*. 2013;11(4):276-85.
12. Phillips AJ, Ostlere SJ, Smith R. Pregnancy-Associated Osteoporosis: Does the Skeleton Recover? *Osteoporos Int*. 2000;11(5):449-54.
13. Zarattini G, Buffoli P, Isabelli G, et al. Pregnancy-associated osteoporosis with seven vertebral compression fractures, a case treated with strontium ranelate. *Clin Cases Miner Bone Metab*. 2014;11(2):139-41.
14. Goldman GA, Friedman S, Hod M, et al. Idiopathic transient osteoporosis of the hip in pregnancy. *Int J Gynecol Obstet*. 1994;46(3):317-20.
15. Lequesne M. Transient osteoporosis of the hip. A nontraumatic variety of Südeck's atrophy. *Ann Rheum Dis*. 1968;27(5):463-71.
16. French AE, Kaplan N, Lishner M, et al. Taking bisphosphonates during pregnancy. *Can Fam Physician*. 2003;49:1281-2.
17. Munns CF, Rauch F, Ward L, et al. Maternal and Fetal Outcome After Long-Term Pamidronate Treatment Before Conception: A Report of Two Cases. *J Bone Miner Res*. 2004;19(10):1742-5.
18. Winarno A, Kyvernitakis I, Hadji P. Successful Treatment of 1-34 Parathyroid Hormone (PTH) after Failure of Bisphosphonate Therapy in a Complex Case of Pregnancy Associated Osteoporosis and Multiple Fractures. *Z Geburtshilfe Neonatol*. 2014;218(04):171-3.
19. Choe EY, Song JE, Park KH, et al. Effect of teriparatide on pregnancy and lactation-associated osteoporosis with multiple vertebral fractures. *J Bone Miner Metab*. 2012;30(5):596-601.
20. Hellmeyer L, Kühnert M, Ziller V, et al. The Use of i. v. Bisphosphonate in Pregnancy-Associated Osteoporosis - Case Study. *Exp Clin Endocrinol Diabetes*. 2007;115(02):139-42.