

An Interesting Case of SARS-CoV-2 (COVID-19) Encephalopathy in a 52-Year-Old Male - Case Report

Vijay Chander Vinod*, Muhammad Umar Younis, Humera Mubarik, Shakeel Ismail and Deeb Kayed

Mediclinic City Hospital, Dubai Healthcare City, Dubai, UAE

*Corresponding author: Vinod VC, Department of Accident & Emergency, Mediclinic City Hospital, Dubai Healthcare City, Dubai, UAE, Tel: +97144359624; E-mail: drvijaychanderv@yahoo.co.uk

Received: September 23, 2021; Accepted: October 05, 2021; Published: October 12, 2021

Abstract

Introduction: Initially recognized as a disease of respiratory system, the information about COVID-19 has evolved gradually and is well established that beyond the respiratory system, as it damages other organs as well. Majority of the COVID-19 patients admitted in hospitals may develop neurological signs and symptoms. We report an interesting case of a 52-year-old male with COVID-19 disease, who presented with symptoms of cardiac / respiratory involvement, but had signs of encephalitis and neuro-cognitive impairment.

Presentation of Case: 52-year-old male patient presented with chest pain, shortness of breath, shivering and sweating. He was tested positive for SARS-CoV-2 (COVID-19) 10 days prior to the presentation. He is known to have hypertension, type 2 diabetes, dyslipidaemia, asthma and congenital nystagmus. He appeared unwell and slightly confused with hesitant speech. Neurological examination revealed hesitant speech, horizontal nystagmus in all directions, myoclonic jerks, ataxia and tremor. Developed seizures during the hospital stay and was started on anti-convulsants. MRI Brain showed nonspecific white matter hyperintensities / small vessel disease and a lumbar puncture returned with a moderately high glucose only while being negative for meningitis/encephalitis multiplex polymerase chain reaction tests. EEG was done to concede theta frequency background slowing waves. Patient was started on pulsed high dose methylprednisolone therapy for cognitive impairment. A 5 day course of intravenous immunoglobulins was then prescribed which allowed resolution of the jerks with marked improvement in his cognitive and motor responses. Patient was discharged home on oral medication on his 19th admission day with regular occupational and physiotherapy sessions as part of his rehabilitation.

Discussion: Severe acute respiratory syndrome coronavirus 2 (SARS-CoV-2), now known as COVID-19 was primarily a disease of the respiratory system. Over the period of time, the virus has invaded the cardiac and the neurovascular system. There is lack of evidence with regards to the exact pathophysiology and the extent of involvement of the central and peripheral nervous system. The exact mechanism and pathophysiology of the neurological manifestation of COVID-19 is less understood and studies are in progress.

Conclusion: COVID-19 is primarily a disease of the respiratory system, within a year of being declared a pandemic, the disease has emerged to have significant cardiac and neurological involvement. Studies are in progress to determine the actual pathophysiology of the neuro-cognitive impairment as the presenting symptom or as an established complication of the COVID-19 disease.

Keywords: COVID-19; SARS-CoV-2; Encephalitis; Encephalopathy; Neuro-cognitive impairment

1. Introduction

Severe acute respiratory syndrome coronavirus 2 (SARS-CoV-2), now known as COVID-19, with the first reported cluster of cases of pneumonia in Wuhan, Hubei Province on Dec 31st, 2019, was declared by World Health Organization (WHO) as public health emergency on January 30th, 2020, and as a Pandemic on March 11th, 2020.

As of March 1st, 2021, COVID-19 cases have soared to over a 100 million in 213 Countries and Territories around the world, with over 2.5 million deaths.

Initially recognized as a disease of respiratory system, the information about COVID-19 has evolved gradually and is well established that beyond the respiratory system, as it damages other organs as well.

Despite of recovering from the illness itself, clinicians are concerned about the possible neuro-cognitive sequelae of the disease in future and the damage it could incur in their day today life.

Majority of the COVID-19 patients admitted in hospitals may develop neurological signs and symptoms [1]. Some of the reported neurological symptoms were headache, dizziness, confusion, myalgia, dysgeusia, and anosmia. Encephalopathy, ataxia, myoclonus, seizures are not that common.

There are few cases reported explaining the possible immune mediated intracranial cytokine storm, seen in both viral and immune mediated encephalitis, resulting in encephalopathy and cognitive impairment [2-5].

A study was done in France with regards to the neuro-cognitive impairment post COVID-19 illness [6].

Prospective studies such as the NeuroCOVID-19 by the National Institute of Health (NIH) are in place to study the prevalence of the neuro-cognitive impairment and encephalopathy due to the virus, and to report the morbidity and mortality [7]

2. Presentation of Case

A 52-year-old male patient was brought to the Emergency Department complaining of chest pain, shortness of breath, shivering and sweating. He started feeling more unwell 3 days prior to arrival to the hospital and was getting progressively worse.

Initially he started feeling unwell 10 days prior, tested positive for Sars-CoV-2 (COVID-19). He isolated himself at home as per the current guidelines.

He is known to have hypertension, type 2 diabetes, dyslipidaemia, asthma and congenital nystagmus. His chronic medications were: Sitagliptin/Metformin 50/1000 mg, Atorvastatin 10 mg and Montelukast 10 mg.

He did not complain of any symptoms of fever, nausea or vomiting, no urinary or bowel symptoms at the time of presentation to the emergency department.

On examination, he appeared unwell, was shivering and slightly confused with hesitant speech. His initial vital signs on arrival were: blood pressure was 145/74 mmHg, pulse rate 118 beats per minute, saturation of 96% on room air, respiratory rate of 18 breaths per minute and a temperature of 36.5 degrees Celsius.

Further clinical examination revealed coarse breath sounds on auscultation, but no crepitation or wheezes were heard. Neurological examination of the patient revealed bilateral horizontal fast nystagmus with corrective saccade, pupil normal size reactive to light bilaterally. There was no deviation of the tongue/uvula and no facial weakness. No sensory deficit in both upper and lower limbs noted. Power in right upper and right lower limbs is 5/5 while power in left upper and left lower limbs was 4/5.

Patient looks anxious and confused but was able to answer all the questions and his memory was intact. He had difficulty in starting the conversation and speech was hesitant. There was no sign of meningeal irritation. Patient was able to perform cerebellar examination tests (finger-nose test and heel shin test) with the right upper and right lower limbs, but he was unable to perform when tests are repeated on the left side.

CT brain was performed to rule out cerebrovascular disease and was reported normal.

Initial blood work up showed a normal Full Blood Count, d-dimer 1.24 (0.0-0.5) ug/ml FEU, normal BNP, negative cardiac markers, random blood glucose 13.31 (<7.8) mmol/L, C-Reactive Protein 64.37 (0-5) mg/L. Normal renal function tests and electrolyte s. ECG showed sinus tachycardia with slight ST depression in leads V3-V5. Chest x-ray showed inhomogeneous opacity seen in the left mid and lower zone as well as the right lower zone keeping with pneumonitis, and management started according to local guidelines.

He was referred to the on-call neurologist because of his history of congenital nystagmus and new onset myoclonic jerks with progressive weakness experienced during home isolation after the positive PCR swab for COVID. He exhibited severe impairment in initiating motor movements with multifocal myoclonic jerks and ataxia. One day into his hospital stay, he suffered a generalized tonic-clonic seizure on the ward with frothing and tongue bite that was aborted using Midazolam and maintenance continued using Levetiracetam. A Magnetic Resonance Imaging study of the brain and cervical spine was done which showed nonspecific white matter hyper intensities / small vessel disease. (FIG. 1-4).

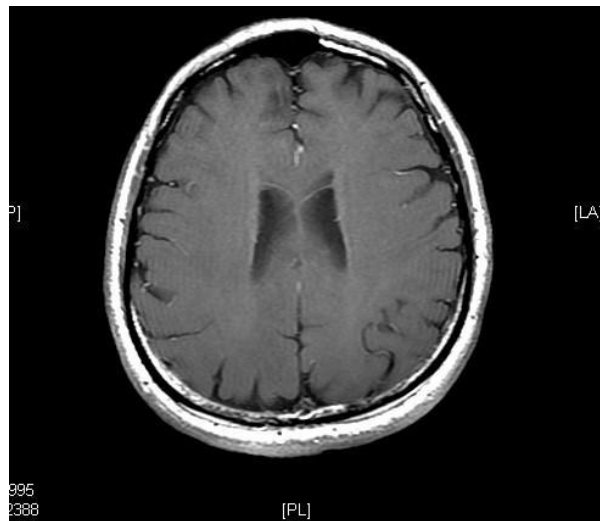


FIG. 1. Bifrontal T1 - Post contrast.

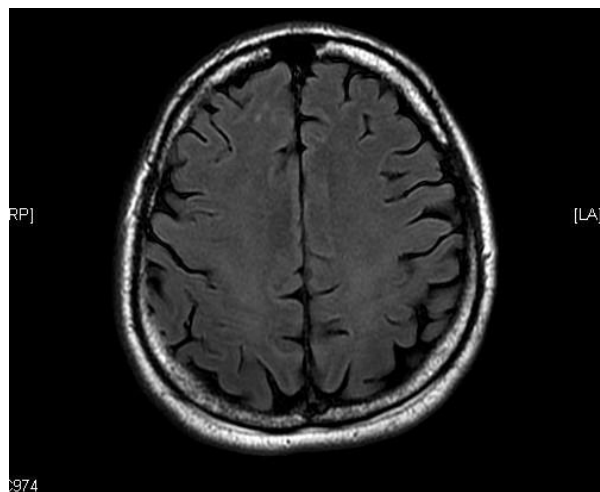


FIG. 2. Bifrontal T2 Flair image.

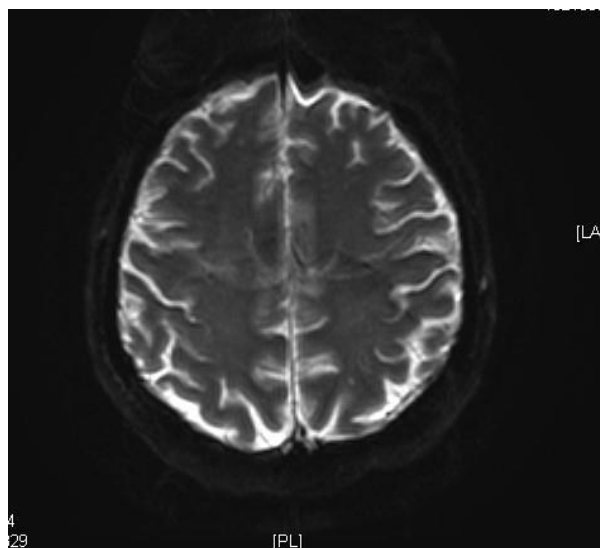


FIG. 3. Bifrontal DWI.

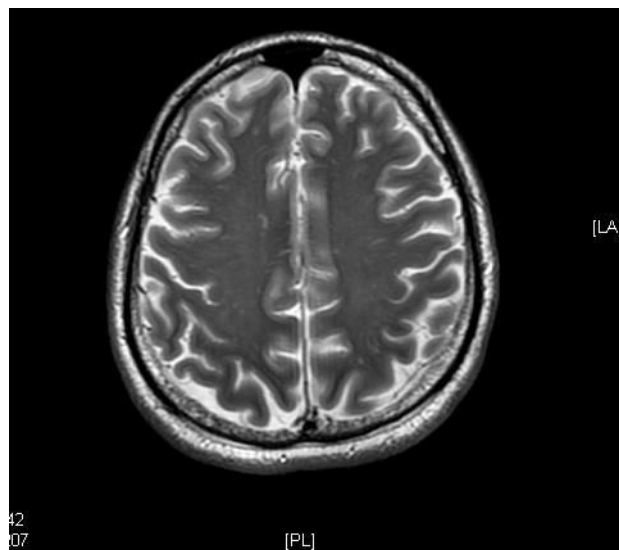


FIG. 4. Bifrontal T2 Flair.

A lumbar puncture returned with a moderately high glucose only while being negative for meningitis/encephalitis multiplex polymerase chain reaction tests. EEG was done to concede theta frequency background slowing waves. Clonazepam was added to the medication regimen which showed pronounced cognitive deficits and decision was taken to start the patient on pulsed high dose methylprednisolone therapy (1g/day for 5 days). Patient showed limited resolution to the pulsed therapy with continued manifestation of myoclonic jerks, psychomotor slowing and cognitive impairment. A 5-day course of intravenous immunoglobulins was then prescribed which allowed resolution of the jerks with marked improvement in his cognitive and motor responses. After 18 days, patient was discharged home on Levetiracetam, Rivaroxoban, and Clonazepam along with his regular medications. He was offered regular occupational and physiotherapy sessions as part of his rehabilitation. He remained on room air maintaining oxygen saturation above 97% during his entire stay at the hospital.

Follow up: Patient was reviewed after 1 week of discharge. Had problem in maintaining balance but has considerably improved. Cognitively improved, but not back to normal. Writing, even short messages, was taking a longer time. Speech is more fluent. Thoughts were better organized. Minimal dysmetria noted. Unable to perform tandem gait maneuvers. Mild wide based gait. Nystagmus (congenital). Speech was still less hesitant. No motor initiation difficulties were noted.

3. Discussion

Severe acute respiratory syndrome coronavirus 2 (SARS-CoV-2), now known as COVID-19 was primarily a disease of the respiratory system. Over the period of time, the virus has invaded the cardiac and the neurovascular system. There is lack of evidence with regards to the exact pathophysiology and the extent of involvement of the central and peripheral nervous system. Studies are in place to determine the same. In a study done in Wuhan, China, approximately 36% of the hospitalized patients with COVID-19 had neurological manifestations at a later date [8].

Some of the reported neurological symptoms were headache, dizziness, confusion, myalgia, dysgeusia, and anosmia. Encephalopathy, ataxia, myoclonus, seizures are not that common. Another study in China showed that COVID-19 patients with severe symptoms developed neurological complications when compared to patients with mild to moderate illness [9].

The exact mechanism and pathophysiology of the neurological manifestation of COVID-19 is less understood and studies are in progress. Angiotensin Converting Enzyme (ACE) - 2 receptor is the main target for COVID-19 virus. These receptors are also found in glial cells of the brain and the spinal cord. There are few proposed mechanisms for the neuro involvement in Covid-19 patients like the migration of the virus from the nasal mucosa to the brain via the cribriform plate, transfer of the virus from the peripheral nerves to the central system via the synaptic route and the damage to the blood brain barrier caused due to the active viremia phase of the illness [10].

There are few cases reported explaining the possible immune mediated intracranial cytokine storm, seen in both viral and immune mediated encephalitis, resulting in encephalopathy and cognitive impairment.

The diagnosis of COVID Encephalitis or Encephalopathy can be quite challenging for the treating clinician as we cannot rely fully on the CSF analysis, EEG and neuro imaging. EEG may show nonspecific spikes. The definitive diagnosis or a clinical feature to confirm viral encephalitis is to isolate the virus from the Cerebrospinal Fluid (CSF), which is quite difficult and not always possible in case of COVID-19 disease. This is due to transient dissemination of the virus and an extremely low titer in the CSF. In a case series, the SARS-CoV-2 virus isolation in the CSF was not possible in all patients presented with COVID encephalitis [11].

As with other viral encephalitis, the treatment is mainly supportive and treated with intravenous steroids, immunoglobulins, immune modulators. Our patient was treated with intravenous steroids and immunoglobulin, showed considerable recovery of his cognitive and motor symptoms. In a case series, about 30% of the patients had residual cognitive impairment after COVID encephalitis [11].

4. Conclusion

COVID-19 is primarily a disease of the respiratory system, within a year of being declared a pandemic, the disease has emerged to have significant cardiac and neurological involvement. Studies are in progress to determine the actual pathophysiology of the neuro-cognitive impairment as the presenting symptom or as an established complication of the COVID-19 disease. We report a 52-year-old male with COVID-19 disease, who presented with signs and symptoms of encephalitis and neuro-cognitive impairment. The absence of established clinical findings on EEG, CSF and neuro imaging, is posing a diagnostic challenge for the treating clinicians, making it a diagnosis of exclusion.

5. Learning Points

Though our patient presented with cardiac / respiratory symptoms, careful examination revealed signs of encephalitis and neuro cognitive impairment. This tells us the presentation was atypical and could have been overlooked.

Isolation of SARS-CoV-2 virus in Cerebrospinal fluid PCR cannot be a definitive criteria to exclude COVID-19 encephalitis.

Pulse steroid therapy and IV Immunoglobulins benefit patients with neuro-cognitive impairment associated with COVID-19 encephalitis.

6. Ethics Approval

Was obtained from the Research & Ethics Committee

7. Patient Consent

Patient has signed the consent form to publish the details of his case as well as the images, maintaining complete anonymity.

REFERENCES

1. Liotta EM, Batra A, Clark JR, et al. Frequent neurologic manifestations and encephalopathy-associated morbidity in COVID-19 patients. *Ann Clin Transl Neurol.* 2020;7(11):2221-30.
2. Poyiadji N, Shahin G, Noujaim D, et al. COVID-19-associated Acute Hemorrhagic Necrotizing Encephalopathy: CT and MRI Features. *Radiology.* 2020;296(2):119-20.
3. Mehta P, McAuley DF, Brown M, et al. COVID-19: consider cytokine storm syndromes and immunosuppression. *Lancet.* 2020;395(10229):P1033-4.
4. Ellul MA, Benjamin L, Singh B, et al. Neurological associations of COVID-19. *Lancet Neurol.* 2020;19(9):767-83.
5. Hebert J, Day GS, Steriade C, et al. Long-Term Cognitive Outcomes in Patients with Autoimmune Encephalitis. *Can J Neurol Sci.* 2018;45(5):540-44.
6. Helms J, Kremer S, Merdji H, et al. Neurologic Features in Severe SARS-CoV-2 Infection. *N Engl J Med.* 2020;382:2268-70.
7. NeuroCovid - a study of Intensive Care-requiring COVID-19 patients - full text view. (Oct 2020). Retrieved March 09, 2021, from <https://clinicaltrials.gov/ct2/show/NCT04578197>
8. Mao L, Jin H, Wang M, et al. Neurologic Manifestations of Hospitalized Patients with Coronavirus Disease 2019 in Wuhan, China. *JAMA Neurol.* 2020;77(6):683-90.
9. Wu Y, Xu X, Chen Z, et al. Nervous system involvement after infection with COVID-19 and other coronaviruses. *Brain Behav Immun.* 2020;87:18-22.
10. Baig AM, Khaleeq A, Ali U, et al. Evidence of the COVID-19 Virus Targeting the CNS: Tissue Distribution, Host-Virus Interaction, and Proposed Neurotropic Mechanisms. *ACS Chem Neurosci.* 2020;11(7):995-8.
11. Helms J, Kremer S, Merdji H, et al. Neurologic Features in Severe SARS-CoV-2 Infection. *N Engl J Med.* 2020;382(23):2268-70.