

Unilateral Aberrant Internal Carotid Artery in the Middle Ear: A Case Report Presenting with Pulsatile Tinnitus

Federica Zoccali^{1*}, Salvatore Martellucci¹, Giuseppe Pelle², Fabrizio Cialente¹, Andrea Gallo¹ and Marco de Vincentiis¹

¹Department of Sense Organs, Sapienza University, Rome, Italy

²Department of Interventional Radiology, Santa Maria Goretti, Latina, Italy

*Corresponding author: Federica Zoccali, MD, Department of Sense Organs, Sapienza University of Rome. Viale del Policlinico 155, 00186, Rome, Italy, Tel: +39 0649976802; E-mail: federica.zoccali@uniroma1.it

Received: June 29, 2022; Accepted: July 09, 2022; Published: July 17, 2022

Abstract

An aberrant internal carotid artery in the middle ear is a potentially disastrous anatomical variation. An accurate diagnosis of this anomaly is essential to prevent catastrophic complications such as massive hemorrhage during otologic procedures. Any intervention on the middle ear without the evaluation of this variation could be fatal, so tomography and magnetic resonance could be very useful to identify this rare entity and to avoid its complications. We report a case of an aberrant internal carotid artery appeared as pulsatile unilateral tinnitus.

1. Introduction

The aberrant course of the internal carotid artery (ICA) in the middle ear is an embryologic vascular malformation of the temporal bone. ICA could show an aberrant lateral course in the temporal bone passing through the middle ear cavity [1]. In literature it is accepted that this abnormal course could be the result of the agenesis of the first embryonic segment of the ICA [1].

The clinical presentation of an aberrant ICA is often nonspecific. It can appear as a red or white mass behind the anteroinferior part of the eardrum in association or not with common clinical symptoms such as hearing loss, pulsatile tinnitus and/or auricular fullness [2,3].

It can be misdiagnosed with glomus tumors, dehiscent jugular bulb, cholesterol granuloma, petrous carotid aneurysms, pseudoaneurysms or hemangiomas [4].

Citation: Zoccali F, Martellucci S, Pelle G, et al. Unilateral Aberrant Internal Carotid Artery in the Middle Ear: A Case Report Presenting with Pulsatile Tinnitus. Clin Case Rep Open Access. 2022;5(3):222.

©2022 Yumed Text.

A misdiagnosis of this anatomical variation could be fatal and may lead to massive bleeding during myringotomy, tympanotomy or surgical procedure performed in the middle ear which could be potentially life threatening [5].

Differential diagnosis could be achieved by high resolution computed tomography, angiography, or magnetic resonance. We report a case about an internal carotid abnormality who showed only pulsatile tinnitus in its clinical presentation.

2. Case Report

A 42-year-old woman presented to Otorhinolaryngology Department of the “Santa Maria Goretti” Hospital (Latina - LT, Italy) with a two-year history of discharge and pulsatile unilateral tinnitus in the right ear. She did not complaint of hearing loss, unsteadiness, or aural fullness.

Her otoscopic examination showed the presence of a pulsatile, bulging, retro tympanic whitish mass with no tympanic membrane perforation. Valsalva maneuver revealed a minimal change in size but not in color (FIG.1).

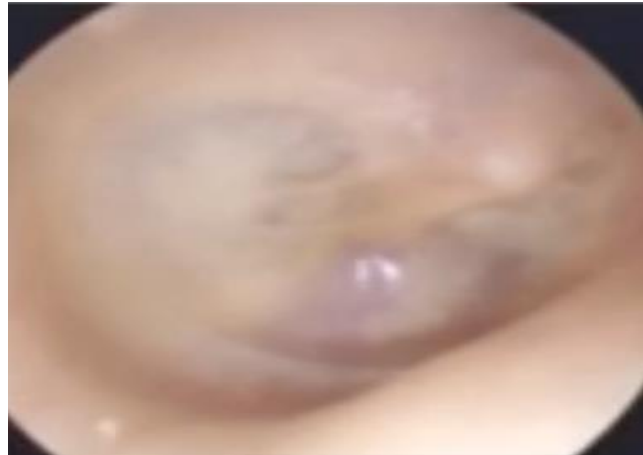

FIG. 1. Right ear otoscopy showing the presence of a pulsatile, bulging, retrotympanic whitish mass with no tympanic membrane perforation.

She had an history of discharge from her right ear but not bleeding lasting several months. We performed an audiometry that showed a little conductive hearing loss on the lowest frequencies in the right ear. While the tympanogram showed a normal “type-A” plotting and nothing was notable with the vestibular balance tests.

She did not refer risks factors such as smoking or drinking habits.

We decided to perform a computerized tomography scan of the temporal bone. A right-sided aberrant ICA with bony dehiscence of the carotid canal was discovered.

Thin section computed tomography (CT) with multiplanar (MPR) and specific bone algorithm reconstruction of the temporal bones, shows an abnormal lateral course of the right internal carotid artery (ICA) that protrudes significantly in the meso/hypo tympanic cavity. CT after intravenous iodinated contrast media injection, confirms the abnormal finding that is consistent with

the diagnosis of aberrant internal carotid artery. Maximum intensity projection (MIP) and Virtual Otoscopy (VO) reconstruction depict close relationship between the aberrant ICA and the manubrium of the malleus (FIG. 2).

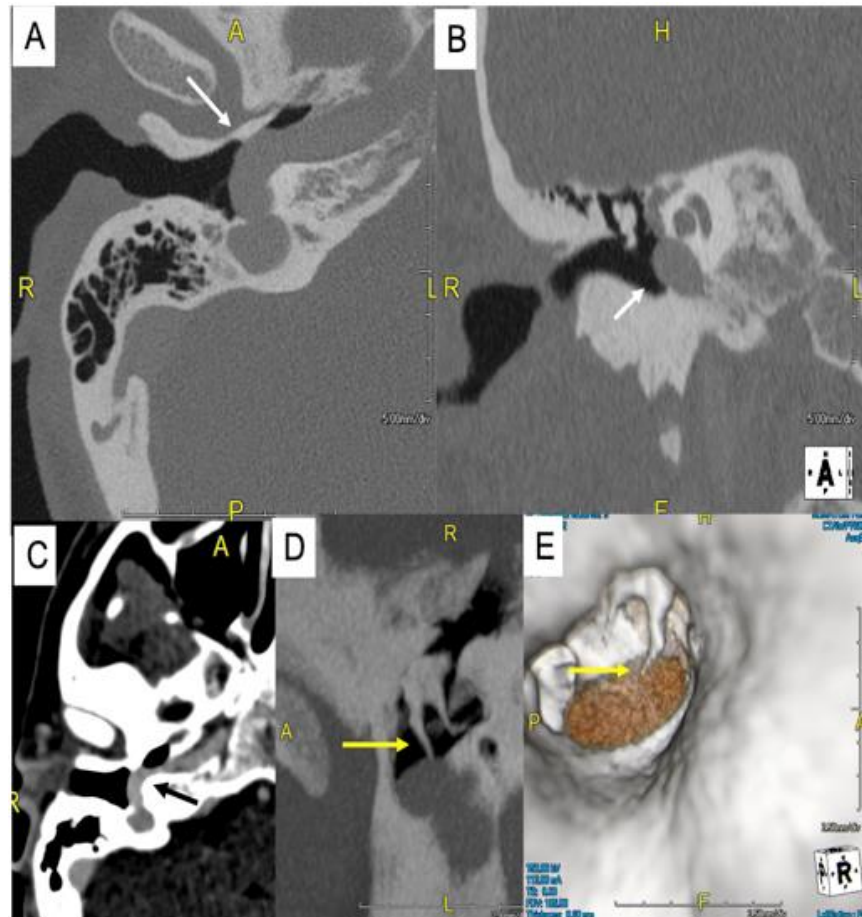


FIG. 2. A, B) Axial and coronal CT projections show large vascular structure (white arrows) protruding in the tympanic cavity. C) CTA confirms the vascular nature of the tympanic finding that is consistent with an aberrant petrous segment of the ICA (black arrow). D) MIP and VO reconstructions show the contiguity of the manubrium of malleus and the ICA (yellow arrows).

The patient was informed about the diagnosis and the possible complications of any middle ear surgery, and she was managed with conservative approach.

Informed consent was obtained in accordance with the ethical standards of Helsinki declaration.

3. Discussion and Conclusions

The internal carotid artery could be anatomically divided into four portions. The petrous tract has a vertical and a horizontal portion along the bony canal in the temporal bone, and it enters the temporal bone medial to the styloid process. The internal carotid's vertical tract is anterior and inferior to the cochlea, and it is separated from the tympanic cavity by a thin plate of bone [6]. If this vertical tract is absent blood supply to the cerebral region is due to the inferior tympanic and caroticotympanic arteries branching from the horizontal internal carotid artery going across the tympanic cavity [7].

Variations of the temporal bone such as the aberrant internal carotid artery, a persistent stapedia artery, high or dehiscent jugular bulb and dehiscent carotid artery canal could be very dangerous during middle ear surgery, even though they are rare [3,8].

Several theories were proposed to explain the presence of an aberrant ICA.

The aberrant ICA is described by More et al. as an enlarged inferior tympanic artery anastomosing with an enlarged caroticotympanic artery, due to an underdevelopment or a regression during embryogenesis of the cervical tract of the ICA [9]. It enters the tympanic cavity through an inferior tympanic canaliculus, going across the tympanic cavity under the cochlear promontory and enter the horizontal carotid canal through a dehiscence in the carotid plate, this condition allows the herniation of the artery into the tympanic cavity [9].

A diffuse accepted theory belongs to Lasjaunias and Santoyo-Vazquez. It enunciates that the persistence of pharyngeal artery causes the passage of the blood from ascending pharyngeal artery to inferior tympanic artery, delaying the progress of the cervical part of ICA [7].

Before attempting surgical manipulation of the middle ear is crucial to perform a differential diagnosis for a pulsating mass behind the eardrum with otosclerosis, glomus tumor or other vascular malformations.

However, a tympanic mass linked to an aberrant ICA looks different from a glomus tumor: anterior, pulsatile, and white or rosy, but it is not always pulsatile such in our case [8].

So, tomography and magnetic resonance imaging of the temporal bone could be very helpful to visualize and diagnose the cause of a pulsating mass mostly before any middle ear surgery if the surgeon has any clinical suspect about the possibility of an AICA [10].

CT has become the standard for diagnosis because it is very helpful in identifying the dehiscence of the bony canal of the ICA and the relation between ICA and middle ear structures.

Clinically and radiologically an aberrant ICA appears as: a soft tissue mass in the middle ear; the reduced caliber of the aberrant carotid; a defective thin bony membrane around the mass which lies from the promontorium to the tympanic membrane; the artery lying below the incudostapedial joint causes conductive hearing loss; a tubular coursing along medial wall of the middle ear along with the horizontal carotid canal; the absence of the proximal tract of the carotid canal and the enlargement of tympanic annulus [10].

Diagnosis of AICA is often difficult because signs and symptoms are nonspecific.

Hearing loss is one of the most common symptoms; others include pulsatile tinnitus (often synchronous with hearth rate), serous otitis media, otalgia, or aural fullness [2,3].

In our patient, the only symptom referred was the presence of a unilateral pulsatile tinnitus.

In case of an asymptomatic AICA most of the authors recommend a conservative approach. On the contrary other authors suggest surgery to relieve the patient of symptoms and to avoid possible destruction of the middle ear structures or the formation of an aneurysm [11].

To minimize tinnitus or in case of chronic middle ear infection a surgical approach could be indicated, including covering the aberrant vessels with soft and bone tissues or topping the graft that touches the exposed ICA [11].

Surgery's benefit is still debated against the risk of possible neurological consequent disorders or serious bleeding complications.

In conclusion, the otolaryngologist had to keep in mind and consider the possibility of an aberrant ICA in otologic patients to prevent possible dramatic surgical complications and a CT scan of the temporal bone should be performed before any middle ear surgery to diagnose such anomalies.

REFERENCES

1. Roll JD, Urban MA, Larson TC, et al. Bilateral aberrant internal carotid arteries with bilateral persistent stapedial arteries and bilateral duplicated internal carotid arteries. *AJNR Am J Neuroradiol.* 2003;24(4):762-5.
2. Windfuhr JP. Aberrant internal carotid artery in the middle ear. *Ann Otol Rhinol Laryngol Suppl.* 2004;192:1-16.
3. Eryilmaz A, Dagli M, Cayonu M, et al. An aberrant internal carotid artery in the temporal bone presenting as a middle-ear mass: a case report. *J Laryngol Otol.* 2008;122(9):983-5.
4. Endo K, Maruyama Y, Tsukatani T, et al. Aberrant internal carotid artery as a cause of objective pulsatile tinnitus. *Auris Nasus Larynx.* 2006;33(4):447-50.
5. Sauvaget E, Paris J, Kici S, et al. Aberrant internal carotid artery in the temporal bone: imaging findings and management. *Arch Otolaryngol Head Neck Surg.* 2006;132(1):86-91.
6. Yetişer S. Aberrant carotid artery in the middle ear. *Balkan Med J.* 2015;32(1):111-3.
7. Lasjaunias P, Santoyo-Vazquez A. Segmental agenesis of the internal carotid artery: angiographic aspects with embryological discussion. *Anat Clin.* 1984;6(2):133-41.
8. Muderris T, Bercin S, Sevil E, et al. A potentially catastrophic anatomical variation: aberrant internal carotid artery in the middle ear cavity. *Case Rep Otolaryngol.* 2013;2013:743021.
9. Moret J, Delvert JC, Bretonneau CH, et al. Vascularization of the ear: normal-variations-glomus tumors. *J Neuroradiol.* 1982;9(3):209-60.
10. Yoshida M, Karino S, Yamasoba T. Aberrant internal carotid artery protruding through a tympanic membrane perforation. *Otolaryngol Head Neck Surg.* 2007;136(4):679-80.