

# Allergic Contact Dermatitis to Povidone Iodine Mimicking Surgical Site Infection - A Diagnostic Dilemma

Karthikayan VR<sup>\*</sup>, Neikhro Zhiemi, Aravind TK and Smit Kishorbhai Raninga

Department of Oncosurgery, Delhi State Cancer Institute, Delhi, India

**\*Corresponding author:** Karthikayan VR, MBBS, MS (General Surgery), DNB (General Surgery), Senior Resident, Department of Oncosurgery, Delhi State Cancer Institute, Dilshad Garden, Delhi- 110095, India, Tel: +91 9643792455/+91 9842286516; E-mail: [doctorvrk@gmail.com](mailto:doctorvrk@gmail.com)

**Received:** March 29, 2023; **Accepted:** April 16, 2023; **Published:** April 24, 2023

## Abstract

**Background:** Polyvinylpyrrolidone-iodine (PVP-I) (Povidone Iodine) is one of the most commonly used antiseptic in the surgical field and is one of the main adjuncts to prevent post-operative wound complications. But very rarely PVP-I usage might cause wound complications in the form of allergic contact dermatitis.

**Case Presentation:** A 54-year-old female diagnosed with ductal carcinoma of the right breast [cT2N1M0] underwent Right Modified Radical Mastectomy (MRM). On the 2<sup>nd</sup> Post-operative day (POD) there was edema, warmth, erythema and tenderness of both the flaps which continued to progress with new onset bullae and blisters. Patch testing revealed the causative agent to be povidone iodine solution used for painting the surgical site, which caused allergic contact dermatitis. The patient improved with systemic antihistamine, topical steroid cream and saline wound dressings.

**Conclusion:** Allergic contact dermatitis secondary to antiseptics should be suspected in any early wound complication. A simple patch test to PVP-I should be done to screen all patients before elective surgery as this helps in avoiding post-operative surgical site complications.

**Keywords:** *Povidone iodine; Allergic contact dermatitis; Patch testing; Chlorhexidine; Carcinoma breast; Case report*

## 1. Introduction

Iodine-based compounds have been used as antiseptics for centuries. Povidone Iodine [an aqueous based iodophore-Polyvinylpyrrolidone-iodine (PVP-I)] is one of the most commonly used antiseptic in the surgical field because of its broad spectrum antimicrobial property, efficacy and safety on nearly all skin surfaces, irrespective of the patient's age. Almost all antiseptics have allergic and irritant properties and among them PVI-P has least irritancy and allergenicity profile [1].

**Citation:** Karthikayan VR, Zhiemi N, Aravind TK, et al. Allergic Contact Dermatitis to Povidone Iodine Mimicking Surgical Site Infection - A Diagnostic Dilemma. Clin Case Rep Open Access. 2023;6(2):250.

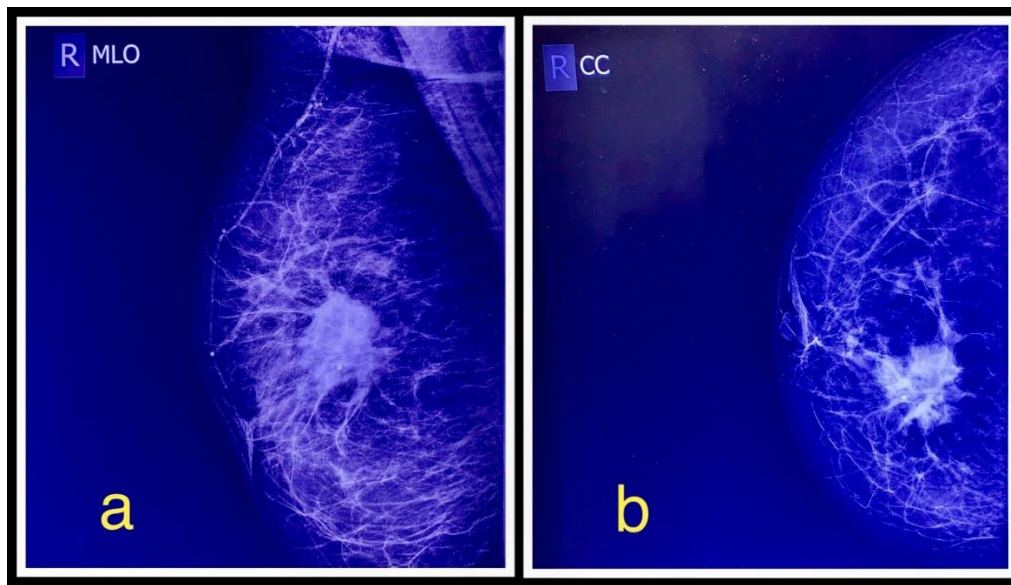
©2023 Yumed Text.

Immediate post-operative surgical site infection is uncommon following breast cancer surgeries and might be due to a breach in antiseptic protocol during surgery. But in our case, it turned out that proper use of antiseptic PVP-I was in fact responsible for allergic contact dermatitis of the flaps, which surprisingly in our patient presented similar to an early infection of the surgical site. Here we are presenting about our patient who underwent Modified Radical Mastectomy (MRM) for carcinoma breast and had a prolonged post-operative course due to a very rare and unique complication, PVP-I induced allergic contact dermatitis.

## 2. Case Presentation

58-year-old post-menopausal female of Indian origin came to our institution with complaints of lump in her right breast for 9 months. She had no family history of breast or ovarian cancer. She did not have any personal or family history of atopy and was not allergic to any food or medications or other substances. She underwent open cholecystectomy for symptomatic gallstone disease 14 years ago and povidone iodine was used for pre-operative skin preparations and for post-operative dressings, but she never developed any allergic reaction to it. She did not have any co-morbidities and all other investigations were normal.

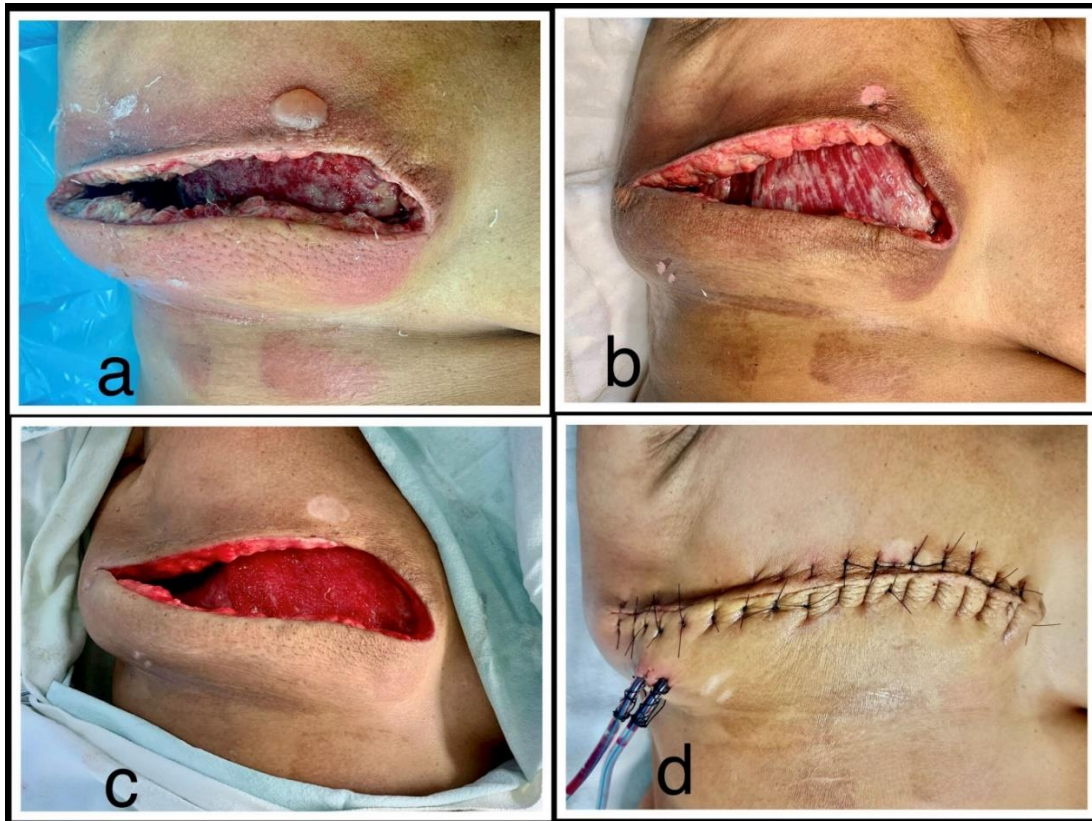
After complete clinical and radiological evaluation, she was found to have a localised ductal carcinoma in the upper inner quadrant of her right breast, the clinical stage being cT2N1M0 - Stage IIB (FIG. 1). Right MRM was planned and as per institutional protocol, 10% povidone iodine was used for painting the surgical site. The surgery was completed without any complications and the patient was recovering well in the immediate post-operative period.



**FIG 1. 1a and 1b- Right breast mammography showing Medio-Lateral Oblique and Cranio-Caudal views respectively. An ill-defined high density mass measuring 3.5 cm × 3.2 cm with speculated margins and coarse calcification seen in the upper inner quadrant of the right breast corresponding to BIRADS 5.**

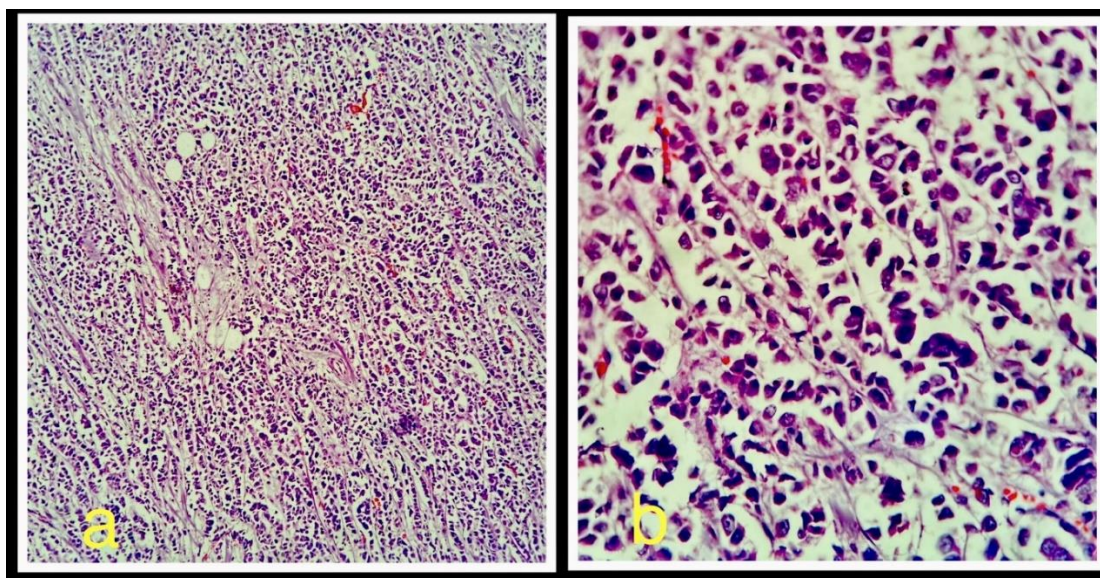
On the 2<sup>nd</sup> Post-operative day (POD) the patient complained of excessive discomfort in surgical site and on examination there was edema, warmth, erythema, and tenderness on both the flaps with minimal serous discharge. A working diagnosis of early surgical site infection (SSI) was made; swab cultures were taken from the wound along with blood cultures and empirical

antibiotics were started to counter commonly encountered microorganisms in SSI's. Sutures had to be removed due to tense edema of the flaps. The preliminary investigation revealed only a slightly raised leukocyte count. Over the next few days, even though the swab culture came as negative, the erythema around the flaps continue to progress with new onset bullae and blisters, without the presence of slough or purulent discharge, arousing suspicion of an allergic reaction. The antibiotics were downgraded, and only saline wound dressing was done. A dermatology consultation was sought and a diagnosis of allergic contact dermatitis was made. Patch testing revealed the causative agent to be povidone iodine solution, which caused a delayed onset hypersensitivity reaction in the form of contact dermatitis. The diagnosis was confirmed by Repeated Open Application Test (ROAT) with PVP-I. The patient improved with systemic antihistamine, topical steroid cream and saline wound dressings. The skin healed well, and secondary suturing was done on 17<sup>th</sup> POD and the patient was discharged well on 19<sup>th</sup> POD (FIG. 2). Mild hypopigmentation of skin was present, which became completely normal by 30<sup>th</sup> POD. The povidone iodine allergy was documented with adequate red flagging, into the hospital record of the patient. Both the patient and her caretakers were informed about the nature of her allergy and were educated to avoid PVP-I in the future.



**FIG. 2. Post-operative surgical site: 2a - Surgical site showing edema, erythema and bullae of the flaps on POD 4; 2b- Surgical site showing partial resolution of the skin changes on POD 8; 2c- Surgical site showing near complete resolution of the skin changes with healthy granulation tissue underneath the flaps on POD 15; 2d- Secondary suturing of the wound done on POD 17.**

The final histopathology came as invasive ductal carcinoma of the breast, not otherwise specified (IDC-NOS), with margins negative (pT2N2a) (FIG. 3). The patient is currently undergoing adjuvant chemotherapy [Dose dense AC (Adriamycin, Cyclophosphamide) → Paclitaxel every 2 weeks] which is to be followed by adjuvant radiotherapy.



**FIG. 3. Histopathology imaging: Hematoxylin and Eosin staining showing invasive ductal carcinoma with malignant cells seen in 10× magnification (3a) and 40× magnification (3b).**

**TIMELINE**

<b>Day</b>	<b>Events</b>
0	Patient presents to the hospital with complaint of right breast lump.
8	Patient was fully evaluated and admitted for surgery.
9	Modified radical mastectomy done with no complications.
11	Patient developed operative site discomfort with edema, tenderness and erythema over the surgical site. Sutures removed; Wound cultures taken.
13	Cultures negative with erythema spreading - diagnosis of allergic contact dermatitis made and appropriate treatment initiated.
26	Wound healed - Secondary suturing done.
28	Patient discharged well.

**3. Discussion**

Preoperative skin painting with antiseptics has drastically reduced the incidence of post-operative SSIs. Chlorhexidine and PVP-I are the most common pre-operative antiseptics used, with no clear winner among them in terms of efficacy. Some researchers claim chlorhexidine to be superior to PVP-I in preventing post-operative SSI in clean contaminated surgery [2] while others claim no significant differences between the two [3]. In terms of safety, PVP-I fares far better than chlorhexidine as it has the lowest irritant and allergic propensity among the commonly used antiseptics, making PVP-I the most widely used antiseptic for surgeries across the globe [1].

In patients with no personal or familial history of increased propensity to allergic reactions, no standard protocol exists for preoperative skin testing for allergens. Even in those with history of atopy or allergy, the most commonly tested agents are antibiotics and anaesthetic drugs with no established testing guidelines for antiseptics [4,5].

Povidone-iodine 10% is a compound of iodine (1% releasable form) and povidone, with additives of glycerin, nonoxynol-9, disodium phosphate, citric acid, sodium hydroxide and polyoxyethylene nonylphenyl ether, with each individual ingredient patch testing not being done routinely [6,7]. Among commonly used antiseptics, hypersensitivity reactions to chlorhexidine are well documented in literature [8], but the ones due to PVP-I are scarce with only a handful of articles documenting its allergic side effects, with even fewer case reports (TABLE 1) depicting post-operative surgical site complications resulting from PVP-I induced dermatitis [7, 9-13]. After topical usage of PVP-I, immediate hypersensitive reaction like anaphylaxis has been reported in only less than 10 cases overall, whereas delayed allergic reaction in the form of dermatitis have been reported in only 50-60 cases [14].

**TABLE 1. Review of similar case reports of PVP-I induced post-operative wound complications.**

<b>Authors</b>	<b>Procedure Performed</b>	<b>Presentation</b>	<b>Diagnostic investigation performed after suspicion</b>	<b>Management</b>
Velázquez et al, 2009 [7].	Carpal tunnel release	Acute vesicular dermatitis of hand and palm on POD 4.	Patch test	Symptomatic
Ancona et al, 1985 [9].	Surgical closure of biliary fistula	Erythematous vesicular rash in back and gluteal region on POD1.	Patch test	Symptomatic.
Rahimi et al, 2010 [10].	Retropubic vaginal sling surgery for stress urinary incontinence	Vulvar edema and acute urinary retention on POD1.	Clinical	Systemic antihistamines.
Reyazulla el al, 2014 [11].	Removal of third molar	Erythematous rash in lower 1/3 <sup>rd</sup> of face on POD1.	Clinical	Topical and systemic steroids, antihistamines.
Zokaie et al, 2014 [12].	Hip replacement	Erythematous blistering rash at the surgical site 4 hours after surgery	Patch test	Symptomatic
Rao et al, 2022 [13].	Low transverse caesarean section	Erythematous lesion with vesicular blisters around the surgical site on POD1.	Clinical	Systemic steroids and antihistamines.

Key: POD1 - Post operative day 1.

Our patient is unique in the sense that not only did she not have any predisposition to allergic reactions but also that she did not have any adverse skin reaction to PVP-I during the previous cholecystectomy surgery, making it very difficult to initially suspect PVP-I induced contact dermatitis in her. Although extremely rare, sensitization to PVP-I have been reported in the literature and this might be one of the reasons our patient developed a reaction only during the second surgery [15]. Even

though pre-operative diagnosis is ideal, and it alerts us to use a different antiseptic during surgery, there are no standard guidelines for the same, making early post-operative diagnosis and prompt treatment all the more important. In spite of its rarity, surgeons should suspect dermatitis due to PVP-I in the early post-operative period, especially in clean surgeries like MRM, as this would help in mitigating the risk of contact dermatitis induced delayed wound healing and predisposition to infection. There is an urgent need for standard diagnostic and treatment protocols, as literature search reveals largely personalised management for PVP-I induced dermatitis.

#### **4. Conclusion**

Even though among the available antiseptics, PVP-I has the least irritant and allergic propensity, incidences of hypersensitivity reaction to it are sporadically reported and hence very much under evaluated. There are no standard preoperative tests to suspect allergy in normal patients and hence there is a critical need for further research to formulate proper pre-operative diagnostic guidelines for screening of all antiseptics and for identifying ways to reduce the allergenicity and irritancy of antiseptics. Till then we advocate a simple, cheap and easy to do patch test with PVP-I to screen all the patients before elective surgery, even in those operated before using the same antiseptic, as this simple test helps in avoiding prolonged post-operative surgical site complications and in reducing morbidity.

#### **5. Abbreviations**

PVP-I: Polyvinylpyrrolidone-iodine/Povidone iodine; MRM: Modified Radical Mastectomy; POD: Post-Operative Day; SSI: Surgical Site Infection.

#### **6. Conflict of Interests**

The authors declare that there is no conflict of interests regarding the publication of this case report.

#### **REFERENCES**

1. Lachapelle JM. A comparison of the irritant and allergenic properties of antiseptics. *Eur J Dermatol.* 2014;24(1):3-9.
2. Chen S, Chen JW, Guo B, et al. Preoperative antiseptics with chlorhexidine versus povidone-iodine for the prevention of surgical site infection: a systematic review and meta-analysis. *World J Sur.* 2020;44(5):1412-24.
3. Ghobrial GM, Wang MY, Green BA, et al. Preoperative skin antiseptics with chlorhexidine gluconate versus povidone-iodine: a prospective analysis of 6959 consecutive spinal surgery patients. *J Neurosurg Spine.* 2018;28(2):209-14.
4. Pfützner W, Brockow K. Perioperative drug reactions - practical recommendations for allergy testing and patient management. *Allergo J Int.* 2018;27(4):126-9.
5. Scolaro RJ, Crilly HM, Maycock EJ, et al. Australian and New Zealand anaesthetic allergy group perioperative anaphylaxis investigation guidelines. *Anaesth Intensive Care.* 2017;45(5):543-55.
6. Lachapelle JM. Allergic contact dermatitis from povidone-iodine: a re-evaluation study. *Contact Dermat.* 2005;52(1):9-10.
7. Velázquez D, Zamberk P, Suárez R, et al. Allergic contact dermatitis to povidone-iodine. *Contact Dermat.* 2009;60(6):348-9.

8. Rose MA, Garcez T, Savic S, et al. Chlorhexidine allergy in the perioperative setting: a narrative review. *Br J Anaesth.* 2019;123(1):e95-103.
9. Ancona A, Suárez de la Torre R, Macotela E. Allergic contact dermatitis from povidone-iodine. *Contact Dermat.* 1985;13(2):66-8.
10. Rahimi S, Lazarou G. Late-onset allergic reaction to povidone-iodine resulting in vulvar edema and urinary retention. *Obstet Gynecol.* 2010;116 Suppl 2:562-4.
11. Reyazulla MA, Gopinath AL, Vaibhav N, et al. An unusual complication of late onset allergic contact dermatitis to povidone iodine in oral & maxillofacial surgery - a report of 2 cases. *Eur Ann Allergy Clin Immunol.* 2014;46(4):157-9.
12. Zokaie S, White IR, McFadden JD. Allergic contact dermatitis caused by iodophor - impregnated surgical incise drape. *Contact Dermat.* 2011;65(5):309.
13. Rao S, Bartkus T, Gandhi K, et al. A post-operative reaction to povidone iodine in a postpartum woman: A case report. *Case Rep Womens Health.* 2022;34:e00394.
14. Xiang BB, Yao YT, Jiao SL. Successful prolonged cardiopulmonary resuscitation after intraoperative cardiac arrest due to povidone-iodine allergy: A case report. *World J Clin Cases.* 2021;9(33):10362-8.
15. Brandao FM, Goossens A, Tosti A. Topical drugs. In: Rycroft RJG, editor. *Textbook of Contact Dermatitis.* 3rd ed. Berlin: Springer, Germany; 2001. 687-723 p.