
Ovarian Dermoid Tumor Masquerading as Rectal Tumor

Ruquaya Mir^{1*} and Meti Gowreesh²

¹Senior Consultant Surgical Oncology, Indraprastha Apollo Hospitals, New Delhi, India

²DNB Trainee Surgical Oncology, Indraprastha Apollo Hospitals, New Delhi, India

*Corresponding author: Ruquaya Mir, Senior Consultant Surgical Oncology, Indraprastha Apollo Hospitals, New Delhi, India, Tel: 011 7179 1090; E-mail: ruquaya.mir@hotmail.com

Received: September 19, 2023; **Accepted:** October 03, 2023; **Published:** October 11, 2023

1. Introduction

Ovarian mature teratoma are benign tumors of the ovary and have been reported in wide age groups ranging from 1 to 91 years [1]. They comprise 10%-15% of cases. They are the most common neoplasms detected in adolescents and during pregnancy. The most commonly known complication is torsion of the tumor, reportedly observed in approximately 16% of cases [2-3]. Meanwhile, formation of fistulas into neighboring organs is an extremely rare complication, occurring in less than 1% of cases and seldom reported [2,4].

We present a rare case of an ovarian teratoma eroding through rectal wall and present with bleeding per rectum on further investigation found to be mature cystic teratoma originating from left ovary.

2. Case Report

A 29-year-old multipara(P2L2A1) female presented with a complaint of lower abdominal pain and bleeding per rectum since 4 months. She did not give any history of urinary disturbance or menstrual abnormalities.

General physical examination revealed no abnormality, and her abdominal examination did not reveal any mass, organomegaly, ascites. Per rectal examination was normal (No abnormality found). Colonoscopic examination shows polypoidal growth noted in the recto-sigmoid region app 15 cm from anal verge. USG abdomen and pelvis shows single large cyst in left adnexa of 10.9 cm × 3.2 cm × 5.3 cm. Blood and biochemical was within normal range. Her show level of tumor markers was CEA- 1.39, CA 125-12.2, CA 19-9 <1.2, AFP- 0.8, betaHCG-1.2 was within normal range. MRI pelvis shows pedunculated polypoidal

mass arising from left lateral wall of sigmoid colon project into recto-sigmoid app 16 cm from anal verge and fallopian tube encased in the lesion, right ovary and uterus was normal (FIG. 1 & 2).

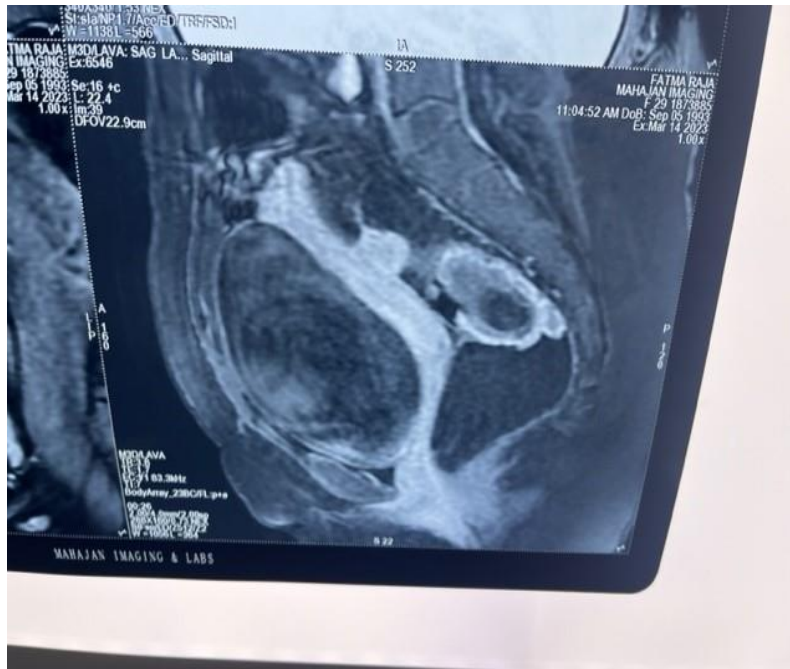


FIG. 1. Sagittal view of MRI showing intra-luminal mass.

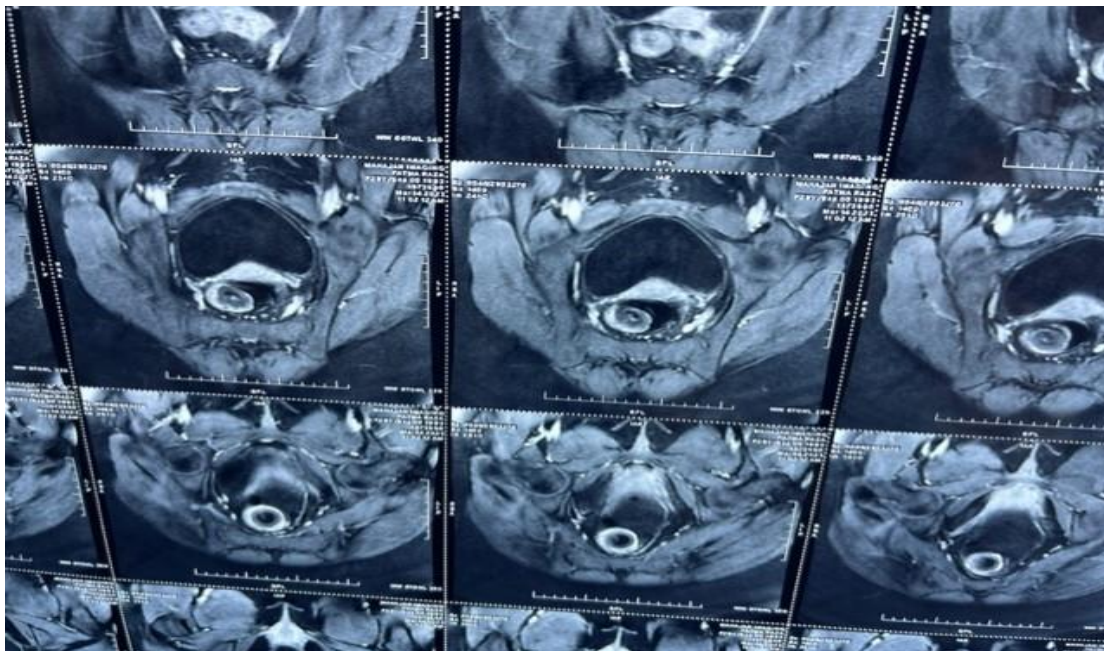


FIG. 2. Coronal view of MRI showing intra-luminal tumor arising from left posterolateral wall.

Exploratory laparotomy was done it shows large left ovarian cystic mass of size (6 cm × 5 cm × 4 cm), invading the sigmoid colon with dense adhesions with sigmoid colon. Uterus and right ovary were healthy. we proceed with left salpingo-

ophorectomy and anterior resection with colorectal anastomosis using circular stapler (CDH). Postoperative progress was satisfactory, and the patient was discharged on day 4.

The final histopathological examination revealed Mature cystic teratoma and surrounding area shows hemorrhage and moderate to dense acute on chronic inflammatory cell infiltration and no evidence of granuloma or malignancy seen (FIG. 3-5).

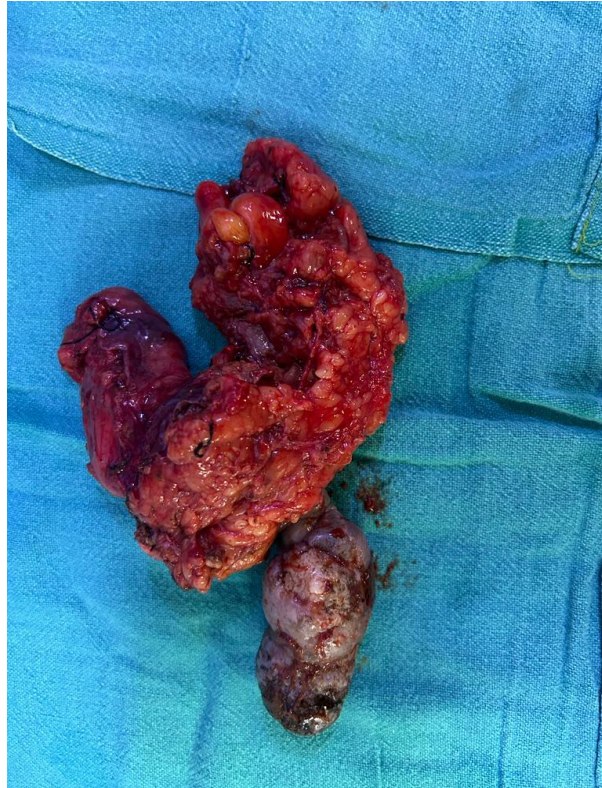

FIG. 3. Anterior resection specimen opened longitudinally showing dermoid tumor.

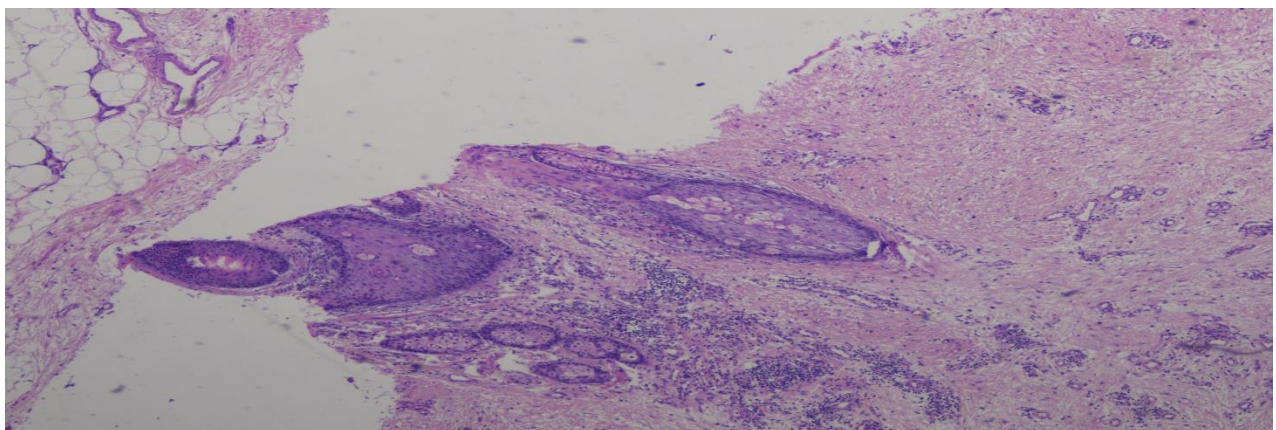


FIG. 4. 100x, H &E Sections show an ovarian mature teratoma with glandular and cystic structures.

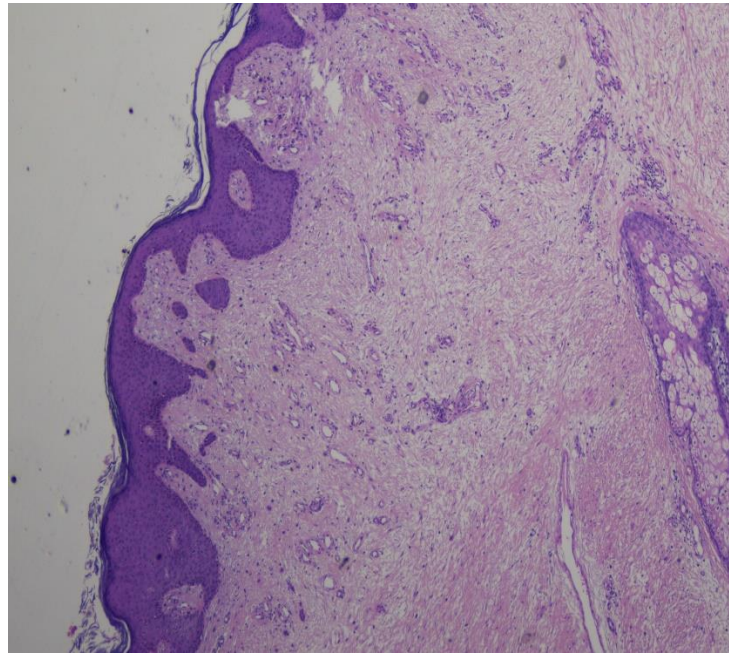


FIG. 5. Section shows Ovarian mature teratoma showing sebaceous glands with intermingled hair follicles.

3. Discussion

Primary rectal teratomas are generally thought to arise from faulty ectodermal cell inclusions during embryogenesis [5]. These do not usually appear until adulthood. Overall, teratomas of the gastrointestinal tract are rare and very few cases of primary rectal teratomas have been reported in literature [6]. The other hand ovarian dermoid is a well-known entity, accounting for 27 to 44% of all primary ovarian tumors, and for 35 to 58% of benign ovarian tumors. Multiple complications are known, of which the most common is torsion (16% of tumors). Other reported complications include rupture (1%-4%), malignant transformation (1%-2 %), and infection (1%) [3]. Meanwhile, the formation of fistulas and invasion into the neighboring organs are extremely rare complications for this tumor, with frequency said to be less than (1 %) [2,3].

Shiels et al. [6] consider the following steps to be involved in the pathogenesis of fistula formation: (1) rupture or perforation of the cyst, (2) small leakage from the cyst causing dense adhesion between the cyst and the surrounding organs, (3) circulatory disturbance of the walls of these structures due to the resultant necrosis and inflammation, and (4) formation of fistulas in the walls of these structures. They postulated that rupture or perforation of the cyst is likely caused by circulatory disorders or infection due to factors such as partial torsion, malignant transformation, and mechanical forces [6]. On occasion, ovarian desmoids with malignant transformation erodes into the intestine [7].

They often themselves present with sudden diarrhea, presence of hairs in stool or recurrent bleeding via rectum. When a teratoma is found in the rectum, it is important to differentiate between a primary rectal teratoma and a teratoma arising primarily from an adjacent organ and eroding into the rectal lumen. According to Fried and Stone [8] a polypoidal growth or the presence of a well-defined pedicle indicates a primary rectal origin. If there is an intra-abdominal component, a CT/MRI

scan is diagnostic. But if the ovarian origin evades detection due to small size, the tumor may be mistakenly diagnosed as a primary rectal teratoma and leads to improper management.

4. Conclusion

The formation of fistulas into neighboring organs is an extremely rare complication of ovarian mature cystic teratomas. While opportunities to encounter such a case in clinical practice seldom arise, if a case is encountered or this complication is suspected, treating doctors must subject to a thorough assessment of the possible causes and with due attention to the avoidance of over or under treatment.

REFERENCES

1. Pantjola E, Noy MA, Axtmayer RW, et al. Ovarian dermoids and their complications: comprehensive historical review. *Obstet Gynecol Surv.* 1975;30(1):1-20.
2. Tandon A, Gulleria K, Gupta S, et al. Mature ovarian dermoid cyst invading the urinary bladder. *Ultrasound Obstet Gynecol* 2010;35(6):751-3.
3. Park SB, Kim JK, Kim KR, et al. Imaging findings of complications and unusual manifestations of ovarian teratomas. *Radiographics.* 2008;28(4):969-83.
4. von Walter AR, Nelken RS. Benign cystic ovarian teratoma with a fistula into the small and large bowel. *Obstet Gynecol.* 2012;119(2 Pt 2):434-6.
5. Takao Y, Shimamoto C, Hazama K, et al. Primary rectal teratoma. EUS features and review of the literature. *Gastrointest Endosc.* 2000;51(3):353-5.
6. Shiels WE, Dueno F, Hernandez E. Ovarian dermoid cyst complicated by an entero-ovarian fistula. *Radiology.* 1986;160(2):443-4.
7. Mitui AH, Fujita R, Sugata F, et al. A case of ovarian dermoid cyst with malignant transformation perforated into the rectosigmoid colon and small intestine. *Endoscopy.* 1983;15(5):331-3.
8. Fried H, Stone HB. Four rare rectal tumors. *Surg Gynecol Obstet.* 1930;50:762-8.