
Two in One, Three in One, and even Four in One. A Short Technical Note

Yakov Perper*

MD, Department of Anesthesiology, Mount Sinai Hospital of Queens, New York, United States

***Corresponding author:** Perper Y, MD, Department of Anesthesiology, Mount Sinai Hospital of Queens, New York, United States, Tel: 718-687-2010; E-mail: yperper@universalpainmanagement.nyc

Received: January 31, 2021; **Accepted:** February 04, 2021; **Published:** February 12, 2021

In Interventional Pain Management, we frequently perform procedures at multiple levels. For example, we often perform transforaminal epidural steroid injections (TESI) at two adjoining levels or middle branch nerve blocks (MBB) at three or four levels. The current technique is to perform an injection at one level, remove the needle, reposition the fluoroscope, and then reinsert the needle through the skin for the injection at the other level. However, skin needle penetration is painful. It takes extra time and increases radiation exposure with needle repositioning. Also, multiple skin penetrations increase the risk of infection [1]. I want to share my technique that allows multiple-level procedure performance with a single needle skin penetration. This is how it is done with L4-L5 TESI:

The C-Arm is tilted cephalad until inferior L5 vertebra endplates are lined up, and then it is angled approximately 45 degrees for a foraminal view. The needle is introduced inside the L5 foramina under fluoroscopic guidance, and an appropriate neurogram is obtained (FIG. 1A). Then, the needle is partially withdrawn. Approximately one-third of the needle remains under the skin. As compared to the L5 injection, the fluoroscope must be tilted caudad in order to have L4 inferior endplates lined up due to the lumbosacral lordosis. This maneuver will bring the needle cephalad and closer to the point of desired needle skin penetration (FIG. 1B). The needle is then fluoroscopically navigated inside the L4 neuroforamina for the L4 nerve block (FIG. 1C).

Similarly, I perform a three-level procedure for lumbar MBBs (FIG. 2) and even four-level for cervical MBBs with a single needle skin penetration.

Although technically more challenging, this method decreases procedural pain, saves time, and diminishes radiation exposure while potentially reducing infection risk.

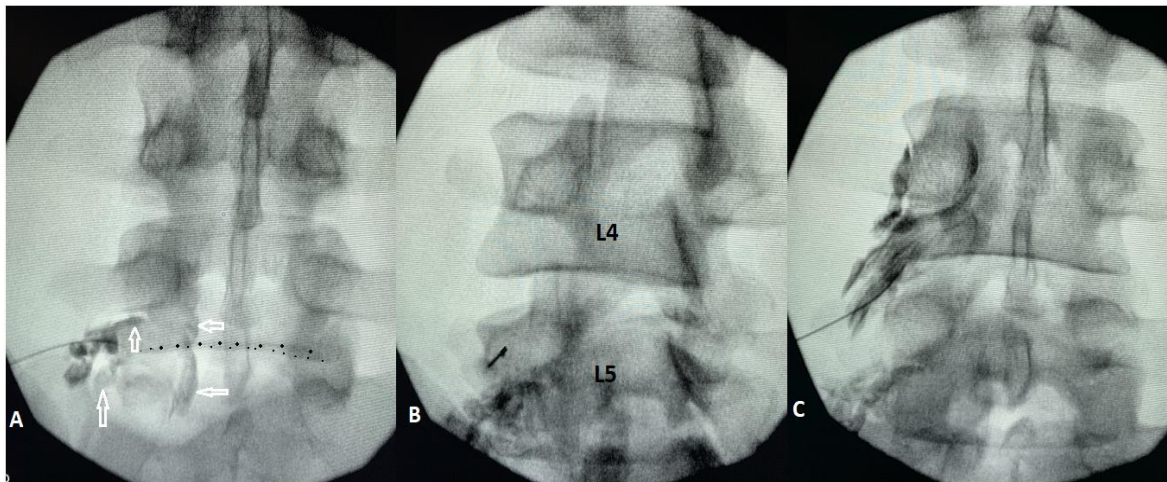


FIG. 1. Two-level TESI with a single needle skin penetration. A. AP view. The needle is positioned for the L5 level with contrast distribution dorsally along the L5 nerve (vertical white arrows) and ventrally into the epidural space (horizontal white arrows). Note inferior anterior endplate (outlined with larger dots) placed in line with inferior posterior endplate (smaller dots). B. Oblique view. The fluoroscope is positioned for L4 injection. Note the needle appears to shift up compared to the initial placement due to the caudad C-Arm tilt. C. AP view. The needle is repositioned for the L4 transforaminal injection.

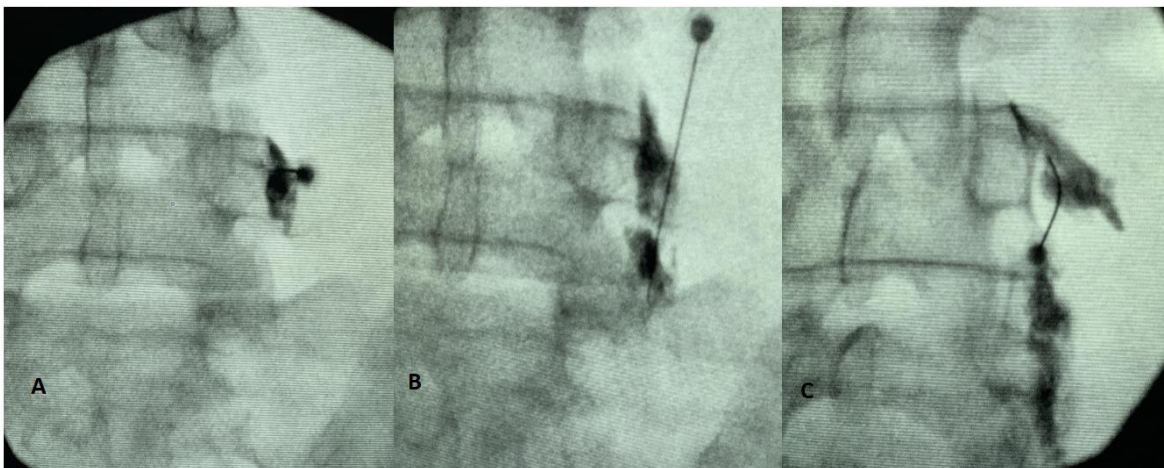


FIG. 2. Three-level MBB with a single needle skin penetration. A. The needle is placed for L4 MBB. B. The needle is repositioned down for L5 MBB. C. The same needle is navigated up for L3 MBB.

REFERENCES

1. Hutin Y, Hauri A, Chiarello L, et al. Best infection control practices for intradermal, subcutaneous, and intramuscular needle injections. Bull World Health Organ. 2003;81(7):491-500.