

## Clinical Signs of Locally Advanced Breast Cancer: All in One

Santhoshkumar Bandegudda\*, Chandra K Naidu and Bollineni Naren

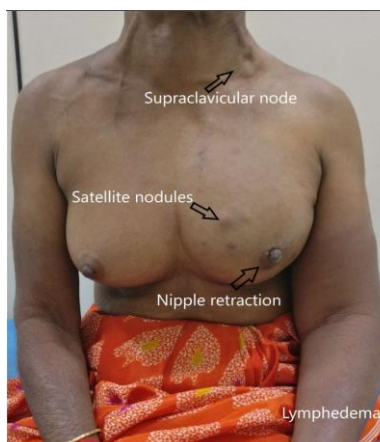
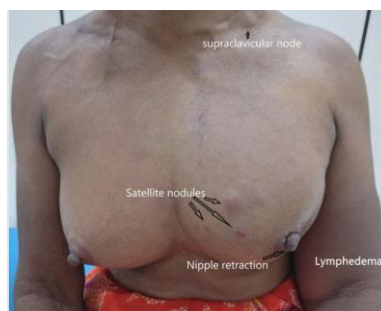Surgical Oncology, Basavatarakam Indo-American Cancer Hospital and Research Institute, India

\*Corresponding author: Bandegudda S, Surgical Oncology, Resident, Basavatarakam Indo-American Cancer Hospital and Research Institute, Hyderabad, Telangana, India, Tel: 040 2355 1235; E-mail: [santupawarkims@gmail.com](mailto:santupawarkims@gmail.com)

Received: May 03, 2021; Accepted: May 19, 2021; Published: May 26, 2021

### Image Description

We are reporting a case of 65-year female presented with swelling in left upper limb and lump in left breast for 1 year, on examination she had a 10 cm × 8 cm mass in the left breast with nipple retraction, satellite nodules, an enlarged left supraclavicular node with left upper limb lymphedema. This photograph here is unique in a way as it depicts all clinical signs of locally advanced breast cancer in one single picture which is rare to find.



**Citation:** Bandegudda S, Naidu CK, Naren B. Clinical Signs of Locally Advanced Breast Cancer: All in One. Clin Med Images Open Access. 2021;2(1):112.

©2021 Yumed Text.