

Diaphragmatic Hernia: A Rare Complication After Neuromuscular Scoliosis Surgery

Luísa Vital*, Sofia Vasconcelos-Castro, Sara A Santos, Joana Freitas, Vitorino Veludo and André Pinho

MD, Centro Hospitalar Universitário São João, Porto, Portugal

*Corresponding author: Vital L, MD, Department of Orthopedics and Traumatology, Centro Hospitalar e Universitário São João, Alameda Professor Hernâni Monteiro, 4200-319 Porto, Portugal, Tel: +351 225512100; E-mail: luisavital1203@gmail.com

Received: July 05, 2020; Accepted: July 15, 2020; Published: July 22, 2020

1. Introduction

Spinal deformity is a common musculoskeletal problem in cerebral palsy [1]. Its incidence and curve pattern depend on the degree of neurologic involvement [2]. Although spinal fusion surgery is the standard treatment for severe neuromuscular scoliosis, due to several comorbidities and deformities its known to be associated with an increased risk of morbidity and mortality [3]. We describe a case of a complication after the surgical treatment of a neuromuscular scoliosis. The patient's tutor was informed that data concerning the case would be submitted for publication, and he provided consent.

2. Case Report

A 16-years-old girl, with past medical history of cerebral palsy and epilepsy, chronically medicated with levetiracetam and diazepam, was referred to our institution due to a severe neuromuscular scoliosis - Gross Motor Function Classification System (GMFCS) 5. She presented a double major curve with a Cobb angle of 49,6° and 51,1° and pelvic obliquity of 11° (FIG. 1). Presenting an American Society of Anesthesiologists' (ASA) score of III, she was submitted to a T3 to iliacs spinal fusion under general anesthesia and with neurophysiologic monitoring; the procedure was performed through a posterior-only approach, without complications, and although there was a drop in hemoglobin values (from 15.5 g/dL to 10.9 g/dL), no blood transfusion was done. Postoperative course was uneventful, and the patient was able to sit on the third postoperative day and was discharged five days later. In the second postoperative month she developed vomiting and increasing feeding difficulties. Three months later, she was admitted to the emergency department due to acute respiratory distress. On physical examination, she presented an increased respiratory rate, increased breathing effort and diminished breath sounds on the lower left hemithorax. A chest radiography revealed the presence of bowel in the left hemithorax (FIG. 2), and a thoracic computed tomography (CT) scan confirmed the presence of a large left diaphragmatic hernia (FIG. 3). After insertion of a nasogastric

Citation: Vital L, Castro SV, Santos SA, et al. Diaphragmatic Hernia: A Rare Complication After Neuromuscular Scoliosis Surgery. J Orthop Spine Surg. 2020;3(1):105.

tube, the breathing difficulties were partially resolved, and an upper gastrointestinal contrast study confirmed a partial migration of the stomach into the left hemithorax (FIG. 4).

The patient underwent laparoscopic repair of the defect: a diaphragmatic tear located posterolaterally to the esophageal hiatus was found. After reduction of the colon and stomach, this defect was found to be in close relation with a visible pedicle screw in the thoracic spine (FIG. 5 and 6). The diaphragmatic defect was then sutured and postoperative course was uneventful.

A spine CT was then performed which showed 3 screw malposition. It was decided to extract these implants and revise the instrumentation, performing a hybrid construction with hooks and screws, which was achieved without any complications. She was discharged two weeks later, clinically stable and tolerating oral feeding, after completing antibiotic therapy prescribed for the respiratory infection diagnosed on admission.

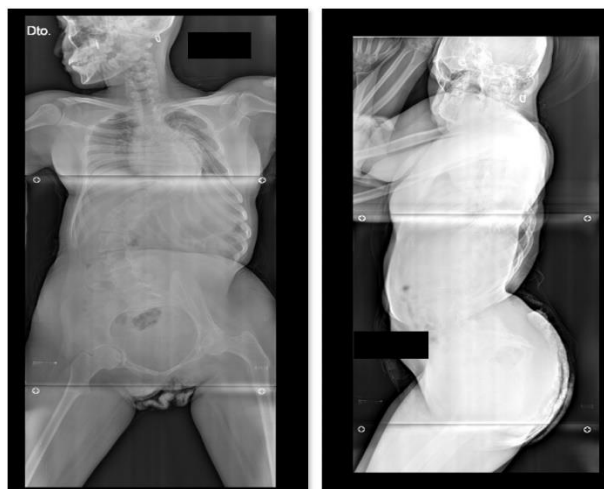


FIG. 1. Preoperative Anteroposterior Radiograph (A) and Lateral (B) Showing a Double Major Curve with Pelvic Obliquity.

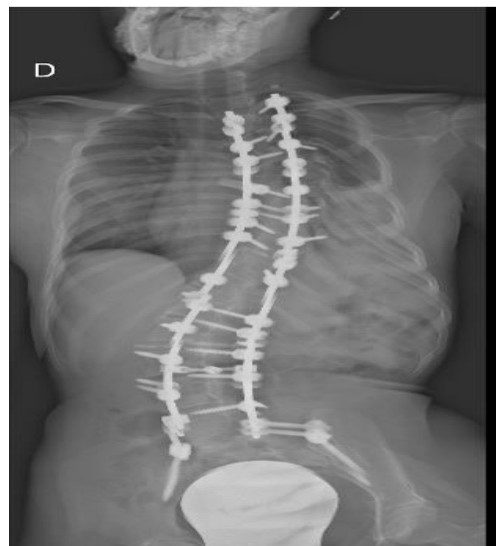

FIG. 2. Thoraco-Abdominal Radiograph: Opacification of Lower Left Hemithorax.

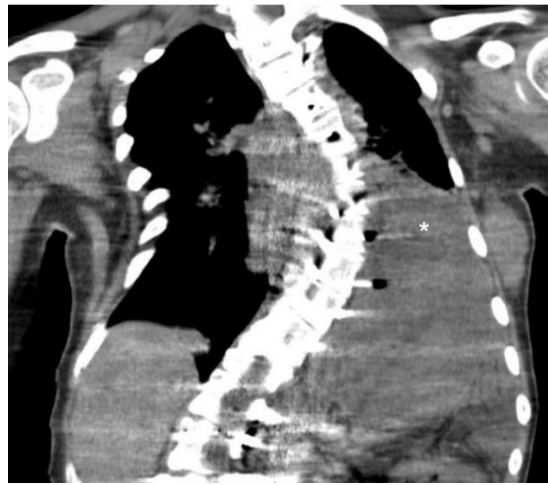


FIG. 3. Thoracic CT Scan: Elevation of Left Diaphragmatic Muscle (*).

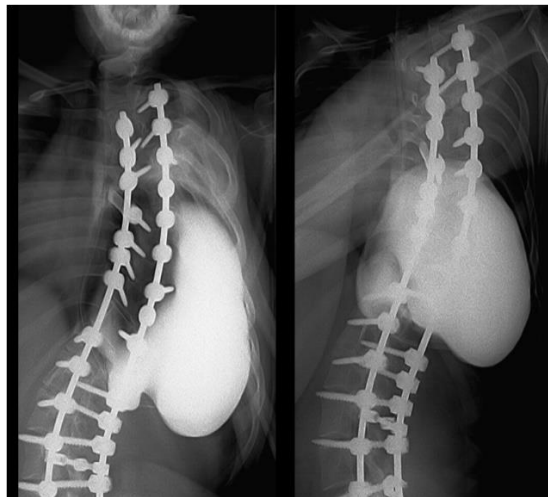


FIG. 4. Upper Gastrointestinal Contrast Study: Stomach Inside the Left Hemithorax.

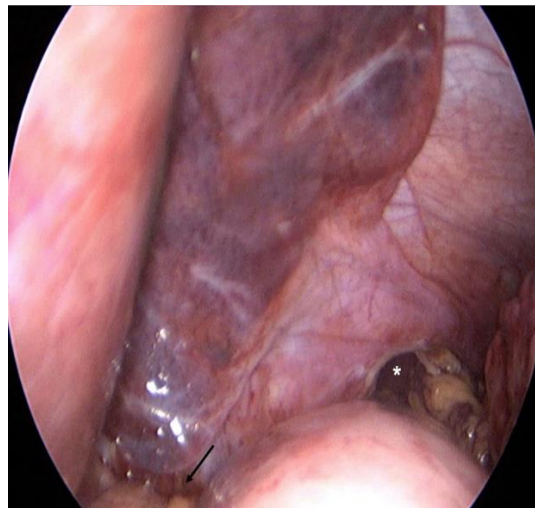


FIG. 5. Laparoscopy: Intraoperative viewing inside the Abdomen, Showing the Diaphragmatic Tear (*) in close relation with the Esophageal Hiatus (Arrow).

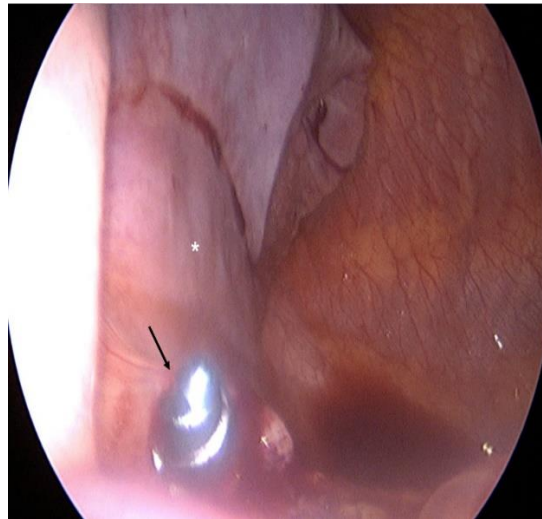


FIG. 6. Laparoscopy: Intraoperative viewing inside the Left Hemithorax, showing a Pedicle Screw (Arrow) in close relation with the Left Lung (*).

3. Discussion

Scoliosis is frequent in cerebral palsy patients with reported incidence that varies from 21% to 64% and increases with GMFCS level and age [4]. The goals of surgical treatment are: correcting the curve in the coronal plane, normalizing sagittal alignment, leveling of the pelvis, restoring coronal balance, and achieving a solid fusion [5]. Surgical treatment of neuromuscular scoliosis is a complex procedure with complication rates that are globally high, despite varying among studies [6]. Cognetti et al. [7] reviewed the Scoliosis Research Society Morbidity and Mortality Database from 2004 to 2015 and reported a complication rate of 6% (1385 complications in 29,019 patients) and in a retrospective analysis Toll et al reported complication rates as high as 27% [8].

Given the underlying pathologies associated with the development of scoliosis in these patients, drawbacks are varied and can include respiratory, gastrointestinal, cardiovascular, neurological, genitourinary, surgical wound and implant complications, some of which are life threatening [9]. The rate of postoperative infection in scoliosis surgery was the subject of a study by Sullivan et al, who demonstrated that in neuromuscular scoliosis the rate of infection is higher when compared to the correction of congenital or idiopathic scoliosis [10].

Regarding the approach, posterior-only approach, as performed in the reported case, it is widely recommended nowadays and a 2018 meta-analysis that compared the single posterior approach with the combined approach concluded that the first one is more advantageous and is associated with shorter surgical times, lower hematic loss, shorter hospital stay and fewer complications [11].

Great effort has been given to preoperatively identify risk factors that could potentiate postoperative complications. Toll et al. demonstrated that the most important risk factors for perioperative major complications are preexisting pulmonary compromise and intraoperative blood loss [8]. In addition, in a retrospective analysis of 131 cases, Master et al stated non-ambulatory status

and preoperative major curve magnitude as risk factors [9]. However, for Basques et al, only the ASA score was an independent predictor of risk in short-term morbidity after posterior spine fusion in neuromuscular scoliosis [12]. Pre and postoperative evaluation is therefore essential to reduce the number of complications [3]. It is therefore imperative to identify the risk factors that increase the rate of morbidity associated with the surgical treatment of neuromuscular scoliosis.

Among the pathologies included in neuromuscular scoliosis, the most representative is cerebral palsy, in which the functional level is classified according to the GMFCS, whose highest and most severe value of 5 corresponds to the case of the reported patient. Jain et al carried out a prospective study to assess quality of life and number of postoperative complications in GMFCS 5 patients and proposed to stratify this group according to neuromotor involvement. The authors conclude that stratification based on central neuromotor impairments can help identify patients with cerebral palsy at GMFCS level 5 who are at higher risk for developing complications after spinal arthrodesis [13]. According to this sub classification, 4 other groups were found and due to our patient's nonverbal status, she can be included in group 5.1.

Gastrointestinal complications are common in the postoperative period of neuromuscular scoliosis, with a reported incidence of 13%. The most common occurrences are paralytic ileus and dysphagia and the risk factors associated with the development of these complications seem to be related to the stiffness of the curve, disturbance in intraoperative spinal cord monitoring and intravenous opioid medication over 5 days postoperatively [14]. The occurrence of diaphragmatic hernia after correction of neuromuscular scoliosis was not found to be reported in existing literature.

The reported case initially presented an unspecified clinical picture that made it difficult to find the final diagnosis. Also, the debility associated with cerebral palsy, makes accurate diagnosis difficult. In this context however, it is important to remember some less frequent diagnoses such as the superior mesenteric artery syndrome [15] or pancreatic fracture [16].

The diagnosis of diaphragmatic hernia was possible through diagnostic exams, but the hypothesis of iatrogenic injury was only placed during the exploratory laparoscopy, when the pedicle screw position and its close relation diaphragmatic defect to the was perceived.

Neurologically impaired patients usually present diaphragmatic defects compatible with hiatus hernias, particularly non isolated diaphragmatic hernias, posterolateral to the esophageal hiatus, as observed in this case [17]. The visible relation with the pedicle screw allowed us to infer an iatrogenic lesion which might be associated with the derotation maneuver or yet with a material conflict during diaphragmatic movements.

Many implants placed during long instrumentations, such as scoliosis, have incorrect positions. However, the indication for their removal is controversial [18]. In this case, due to the evidence of injury and its consequences, we chose to remove the incorrectly positioned screws, achieving a hybrid assembly and eliminating a source of possible complications. Despite the associated complications, studies have shown there is a benefit in scoliosis correction surgery in patients with cerebral palsy - GMFCS IV / V. Current studies show that the quality of life improvement outweighs the risks and persists throughout follow-up [19,20]. Diaphragmatic tear is a possible postoperative complication after scoliosis repair. Medical community should be aware of this threatening complication in order to make an early diagnosis and repair it before further patients' deterioration.

REFERENCES

1. Koop SE. Scoliosis in cerebral palsy. *Dev Med Child Neurol.* 2009;51(Suppl 4):92-8.
2. Häggglund G, Pettersson K, Czuba T, et al. Incidence of scoliosis in cerebral palsy. *Acta Orthop.* 2018;89(4): 443-7.
3. Turturro F, Montanaro A, Calderaro C, et al. Rate of complications due to neuromuscular scoliosis spine surgery in a 30-years consecutive series. *Eur Spine J.* 2017;26(Suppl 4):539-45.
4. Persson-Bunke M, Häggglund G, Lauge-Pedersen H, et al. Scoliosis in a total population of children with cerebral palsy. *Spine.* 2012;37(12):E708-13.
5. Heary RF, Albert TJ. *Spinal Deformities: The Essentials.* 2nd ed. New York: Thieme, USA; 2014.
6. Sharma S, Wu C, Andersen T, et al. Prevalence of complications in neuromuscular scoliosis surgery: a literature meta-analysis from the past 15 years. *Eur Spine J.* 2013;22(6):1230-49.
7. Cognetti D, Keeny HM, Samdani AF, et al. Neuromuscular scoliosis complication rates from 2004 to 2015: a report from the Scoliosis Research Society Morbidity and Mortality database. *Neurosurg Focus.* 2017;43(4):E10.
8. Toll BJ, Samdani AF, Janjua MB, et al. Perioperative complications and risk factors in neuromuscular scoliosis surgery. *J Neurosurg Pediatr.* 2018;22(2):207-13.
9. Master DL, Son-Hing JP, Poe-Kochert C, et al. Risk factors for major complications after surgery for neuromuscular scoliosis. *Spine.* 2011;36(7):564-71.
10. Sullivan BT, Abousamra O, Puvanesarajah V, et al. Deep Infections After Pediatric Spinal Arthrodesis: Differences Exist with Idiopathic, Neuromuscular, or Genetic and Syndromic Cause of Deformity. *J Bone Joint Surg Am.* 2019;101(24):2219-25.
11. Shao ZX, Fang X, Lv QB, et al. Comparison of combined anterior-posterior approach versus posterior-only approach in neuromuscular scoliosis: a systematic review and meta-analysis. *Eur Spine J.* 2018;27(9):2213-22.
12. Basques BA, Chung SH, Lukasiewicz AM, et al. Predicting Short-term Morbidity in Patients Undergoing Posterior Spinal Fusion for Neuromuscular Scoliosis. *Spine.* 2015;40(24):1910-7.
13. Jain A, Sponseller PD, Shah SA, et al. Sub classification of GMFCS Level-5 Cerebral Palsy as a Predictor of Complications and Health-Related Quality of Life After Spinal Arthrodesis. *J Bone Joint Surg Am.* 2016;98(21):1821-8.
14. Jalanko T, Helenius I, Pakarinen M, et al. Gastrointestinal Complications After Surgical Correction of Neuromuscular Scoliosis: A Retrospective Cohort Study. *Scand J Surg.* 2018;107(3):252-9.
15. Rai RR, Shah S, Palliyil NS, et al. Superior Mesenteric Artery Syndrome Complicating Spinal Deformity Correction Surgery: A Case Report and Review of the Literature. *JBJS Case Connector.* 2019;9(4):e0497.
16. Juricic M Jr., Pinnagoda K, Lakhil W, et al. Pancreatic fracture: a rare complication following scoliosis surgery. *Eur Spine J.* 2018;27(9):2095-9.
17. Gezer HÖ, Ezer SS, Temiz A, et al. Boix-Ochoa (Partial Fundoplication) Treats Reflux, Even in Neurologically Impaired Patients. Can it Take the Title of "Gold Standard" from Total Fundoplication? *J Gastrointest Surg.* 2019;23(12):2338-45.
18. Abola MV, Hardesty CK, Knapik DM, et al. Incidence of complete spinal instrumentation removal following surgery for spinal deformity: a 22-year single institution study. *J Pediatr Orthop B.* 2019;28(4):380-4.
19. Miyajima F, Nasto LA, Sponseller PD, et al. Assessing the Risk-Benefit Ratio of Scoliosis Surgery in Cerebral Palsy: Surgery Is Worth It. *J Bone Joint Surg Am.* 2018;100(7):556-63.

20. Murphy RF, Mooney JF 3rd. Current concepts in neuromuscular scoliosis. *Curr Rev Musculoskelet Med.* 2019;12(2):220-7.