

## Solitary Extradural Plasmocytoma: Case Report

**Andres Cobar Bustamante<sup>\*1,3</sup>, Mario German Gonzalez Tenorio<sup>2</sup> and Miguel Martinez Guillermo<sup>1</sup>**

<sup>1</sup>Orthopedic surgeon, Spine surgery fellow, Imbanaco Hospital, Cali, Colombia

<sup>2</sup>Spine Surgeon, Imbanaco Hospital, Cali, Colombia

<sup>3</sup>TYO updated research group, Guatemala, Guatemala

\***Corresponding author:** Cobar A, Orthopedic surgeon, Spine surgery fellow, Imbanaco Hospital, Cali, Colombia, Tel: +502 57095658; E-mail: [acobar4@gmail.com](mailto:acobar4@gmail.com)

**Received:** September 24, 2018; **Accepted:** October 15, 2018; **Published:** October 18, 2018

### 1. Introduction

Extradural Plasmocytoma (EDP) is only known from a small number of cases with poor prognosis, so the clinical characteristics, treatment protocol, prognostic factors, and natural course remain unclear [1]. Plasmocytoma is a rare lesion that accounts for 5% of all plasma cell neoplasms [2]. Few case reports have been published with similar characteristics (TABLE 1). We present a 54-year-old female patient with a solitary but broad lesion with compressive myelopathic symptoms and an insidious clinical onset. The results may suggest that initial surgical intervention followed by radiotherapy is beneficial for symptomatic relief of EDP patients. EDP should be included in the differential diagnosis of any extradural lesion. Hemilaminectomy showed to be effective for symptomatic relief and neurological improvement in the acute onset of spinal cord compression, but radiotherapy has proven to be successful in preventing relapse. Further research is necessary to establish treatment recommendations.

TABLE 1. Previous case reports of extradural solitary plasmocytomas.

Authors	Year	Level	Follow-up	Results
Matsui et al. [22]	1992	L3	19 months	Initial remission followed by recurrence and death
Palmbach et al. [9]	1996	C7-L2/3	7 months	Same
Watanabe et al. [21]	2000	C7-T12	12 months	Same
Hu et al. [19]	2001	L5-S1	5 months	Same
Okacha et al. [17]	2008	T4-T6	6 months	Same
Avadhani et al. [18]	2010	T6-T7	6 months	Improved
Lourbopoulos et al. [20]	2010	C4-C7	13 months	Improved
Kumar et al. [16]	2013	T6-T7	6 months	Improved
Cobar et al , present case	2017	C6-T8	3 years	Improved

## 2. Statement of Informed Consent

The patient was informed that data concerning the case would be submitted for publication, and he provided consent.

## 3. Case Report

We present a 54-year-old woman that was brought to the emergency department due to 5-month history of cervical and upper-back pain. The main complaint was paresthesia and palsy of the four extremities. She had no history of infectious, tumoral or degenerative diseases; weight loss, night sweats or history of fever was also denied. She presented numbness of upper and lower limbs, weakness, gait disturbances, difficulty urinating and back pain that had increased to 8/10 on the visual analog scale (VAS) over the last 5 months. Physical exam revealed limited range of movement in neck, bilateral Babinski sign, generalized hyperreflexia and lower limb muscular strength of 3/5 on Daniels scale, grade 3 spasticity and decreased temperature perception. Magnetic resonance imaging (MRI) of the cervico-thoracic spine revealed mild compression of the cord with slight hypo-T1/hypo-T2 signal intensity from C6 to T8 surrounding the dural sac (FIG. 1). After gadolinium administration, a large irregular area of homogeneous contrast enhancement surrounding the cord at the ventral and dorsal periphery of the mentioned levels was seen (FIG. 2).

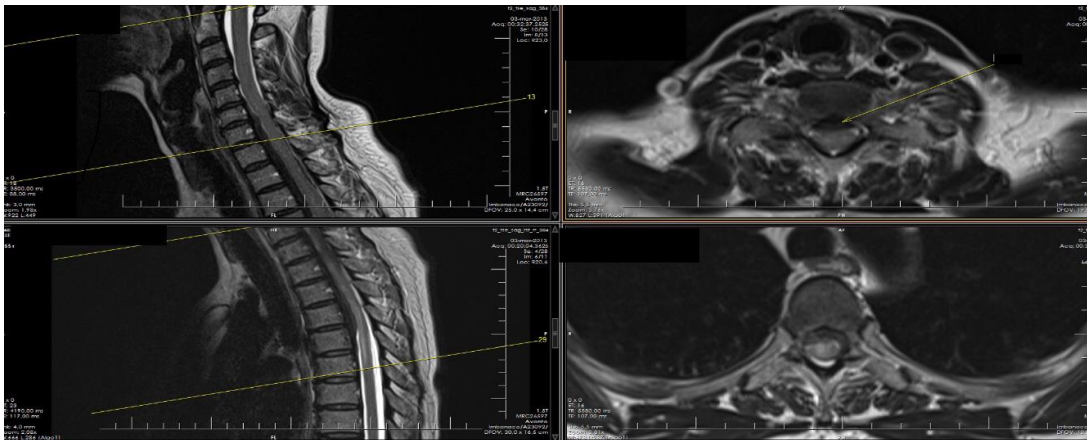


FIG. 1. Initial MRI (T2 weighted image) of Cervico-thoracic spine with extradural anterior mass with low signal intensity.

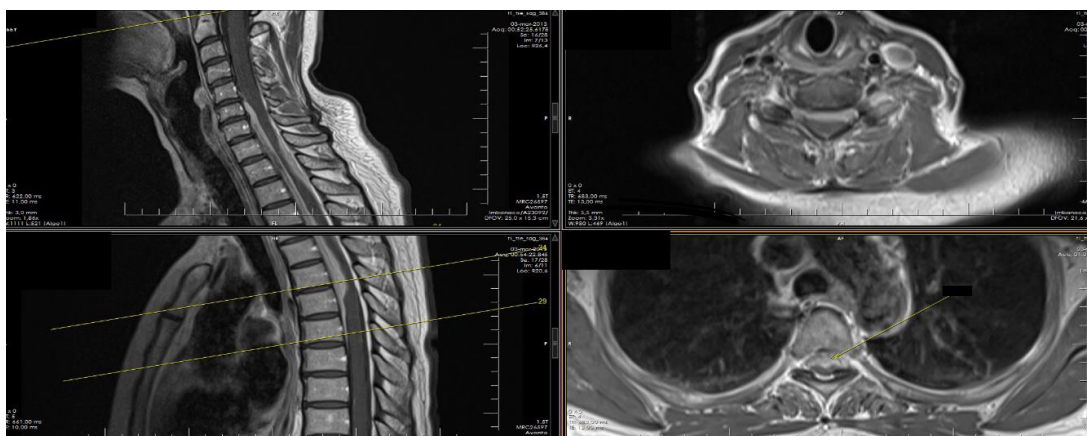

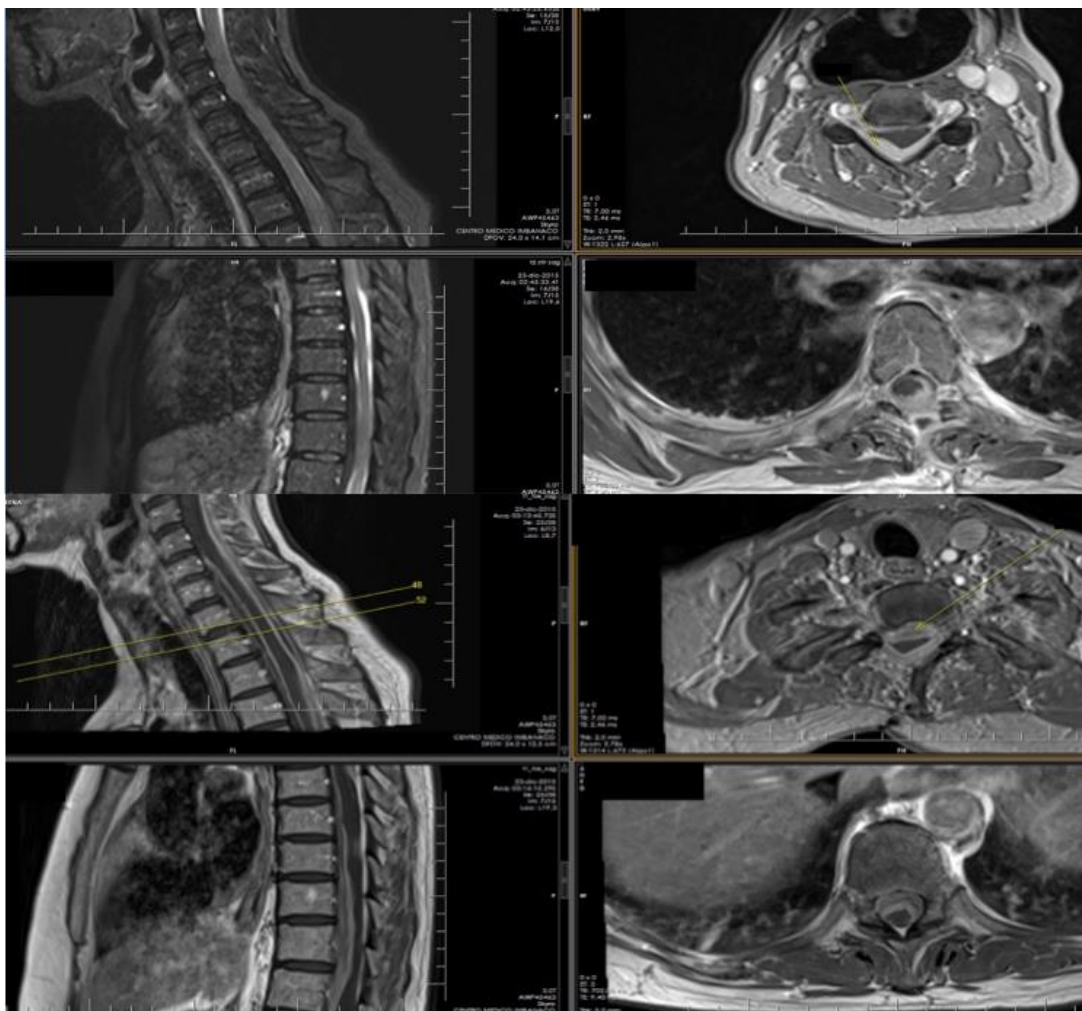
FIG. 2. Initial MRI with Gadolinium contrast medium that enhances extradural mass.

Laboratory findings including blood urea nitrogen, creatinine, C-reactive protein, white blood cell count, and total protein were normal. Antinuclear antibodies were not detected. A lumbar puncture revealed clear cerebrospinal fluid without any cells, normal protein levels, electrophoresis and immunofixation, as well as normal glucose levels; HIV antibodies, blood cultures were reported negative.

Due to the clinical presentation and lack of risk factors in patients' medical history the initial diagnosis was considered to be epidural abscess versus tumoral lesion. She had clinical signs of spinal cord compression and risk of permanent damage. Surgical decompression was considered to take first priority and the patient was sent to the operating room. Patient was in prone position, standard surgical site preparation and preoperative checklists were done; spinal segments to decompress were identified fluoroscopically. Prophylactic antibiotics were administered 30 minutes previous to skin incision. Standard dorsal approach was chosen. Right-sided hemilaminectomy starting at the C6 level and ending at de T8 level was performed, based on the distribution of the extradural mass in MRI and the lesion was visualized immediately after hemilaminectomy. The dura appeared hypervascularized; samples were sent for pathology analysis in isotonic saline solution and cultures were requested; partial resection was done due to elevated blood loss during surgery (1800 cc). No surgical complications were reported. No instrumentation was considered necessary because facet joints were preserved. There were no intraoperative images taken. Patient's neurological status improved immediately after surgery, but wheel chair was still necessary due to residual generalized spasticity and palsy.

The sample was reported as chronic inflammatory cells, with no specific pathological diagnosis and cultures were negative. Broad spectrum antibiotic treatment was administered for 8 weeks, with mild improvement. Complete workup for multiple myeloma including skeletal survey, bone marrow biopsy, protein electrophoresis and serum immunoglobulin and gamma globulin free light chain assessment were reported as normal. Physical therapy program had been enrolled and improvements in spasticity were reported. Nearly 4 months later patient reported that she had recovered independent gait but with persistent moderate spasticity.

24 months after first surgery, patient has a relapse of symptoms, on this occasion the patient was presenting with progressing hemiparesis and acute dorsal pain. A new MRI (FIG. 3) reveals spinal cord compression and extradural mass at the same levels of previous episode. The patient is admitted to the operating room for revision surgery and decompression. The same surgery protocol was followed and enough tissue was obtained to analyze. Adequate decompression of spinal cord was accomplished. Pathology report was described as: leukocyte infiltrates that were mainly located perivascularly, within an inflammatory reactive infiltrate predominantly consisting of CD45, CD38 and CD20 positive and CD 56 negative cells. The tumor was confirmed as EMP. There were mild clinical improvements after surgery. The follow-up MRI revealed no changes at 2 years. As the final diagnosis was plasmocytoma, the patient was immediately treated with radiotherapy in 2 Gy fractions up to a total dose of 44 Gy combined with systemic dexamethasone treatment. After radiation, moderate improvement of the neurological symptoms of the patient was observed and even more improvement after completing the physical therapy program, achieving almost normal gait with mild spasticity. She developed esophagitis due to radiation but resolved quickly after. Follow-up MRI 12 weeks after the end of the radiotherapy did not reveal lesion improvement. On her 3-year follow up, the patient presents with independent gait with mild spasticity, no sensitivity abnormalities, no pain and a Oswestry Disability Index (ODI) of 18.



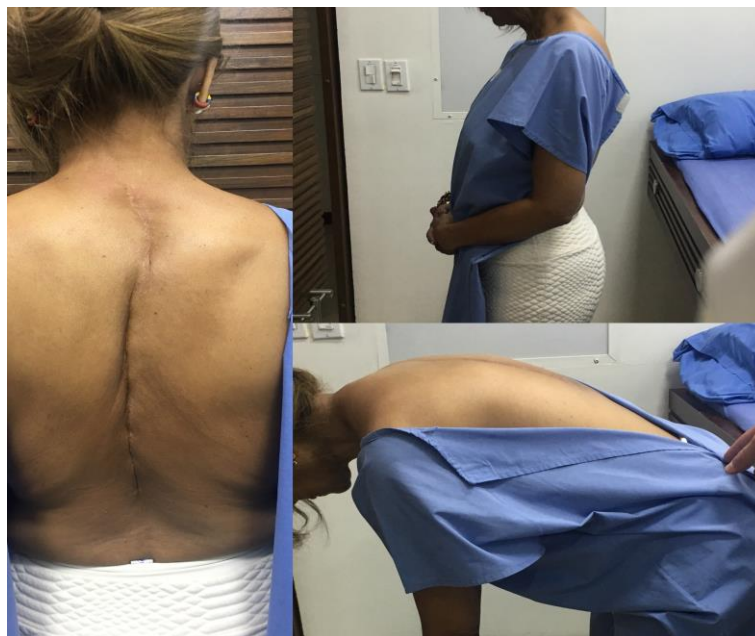**FIG. 3. T2 weighted (upper images) MRI and with Gadolinium contrast medium (lower images) in relapse setting showing anterior and posterior compression of spinal cord.**

#### 4. Discussion

Extradural Plasmocytoma (EDP) is only known from the small number of cases with poor prognosis, so the clinical characteristics, treatment protocol, prognostic factors, and natural course remain unclear. Hans F, et al. [1] reported a cervical extradural plasmocytoma, treating it with chemotherapy followed by radiotherapy and corticosteroids without any improvement [1]. Plasmocytoma is a rare lesion that accounts for 5% of all plasma cell neoplasms [2,3] The bony structures forming the spinal canal, vertebral bodies, and spinous processes remained intact in our patient, in spite of extensive involvement of the spinal canal by the tumor involving ten vertebral levels. Such preservation of the bony structures is common to all reported cases of SEP, so extradural tumor located in the spinal canal without bony changes may be a neuroimaging characteristic of SEP, as reported by Tsutsumi S, et al. [3].Magnetic resonance imaging (MRI), commonly used to evaluate the spine in patients presenting with pain, can further characterize lesions that may be encountered on other imaging studies, other advantages are superior contrast agent resolution that play an important role in assessing tumor location, directing biopsy, planning proper therapy and in evaluating therapeutic results. Dural lesions are usually rather well defined and have a slight hyposignal on T1-weighted image (WI) and T2WI with moderate homogeneous contrast enhancement, which have to be differentiated from other intradural extramedullary lesions such as meningiomas or nerve

sheath tumor [4] Definite diagnosis of these lesions can be made only by pathology and immunohistochemical studies. Malignant plasma cells can be found in both plasmacytoma and B-cell non-Hodgkin lymphoma with plasmacytic differentiation; however, plasmacytomas as well as multiple myeloma can be identified by the expression of the CD138 and the CD38 antigen as well as immunoglobulin light chains [5]. Decompression relieves patients of their acute neurological deficits before permanent cord damage has set in. In addition, radiotherapy and oncological treatment have prolonged life expectancy as well as the quality of life. Radiotherapy has also proved to be useful to decrease relapse. Spinal instability resulting from direct involvement of the supporting structures of the spine or due to the surgical procedure per se, must be considered and if adequate decompression leads to iatrogenic instability, obligating the surgeon to stabilize and fuse the spine [6]. There was recurrence after initial decompression due to lack of histological evidence, leading to improper treatment at first contact but no relapse was reported after postoperative radiotherapy in the second occasion. Until now, there is still no standard treatment of SEP of the CNS. There have been reports of intrathecal chemotherapy, surgical removal, and radiation therapy. Those located within the brain parenchyma and possibly the spinal cord, as seen in our case; appear to be associated with a less favorable response [6]. Plasmacytoma should be considered when extradural mass is presented as an MRI finding and atypical features are observed. If the lesion is anatomically resectable, histopathological evaluation is essential [7,8]. Neurological compression in plasmacytoma occurs in approximately 5% of patients [9-12]

Our patient showed satisfactory functional outcome (FIG. 4). Radiotherapy has been established as a successful treatment and different protocols have been used in individual cases, to avoid transformation to multiple myeloma, which occurs in 50% of the cases within 5 years [10,11]. Plasmacytoma have a significantly higher 5-year survival rate compared to multiple myeloma, which is 75% vs 32%, respectively [13,14]. Knobel et al. [15] demonstrated that, in solitary tumors less than 5 cm in size, local control was attained with moderate dose radiation at a rate of 91%; and 73% in those >5 cm. Extradural Plasmacytoma causing compressive myelopathy is exceedingly rare, and to the best of our knowledge, only a few cases have been reported in literature [16-22].



**FIG. 4. Healed surgical wound (left). Independent stand up position (upper right). Adequate mobility (lower right).**

## 5. Conclusions

EDP should be included in the differential diagnosis of an extradural tumor located in the dorsal spinal canal without associated bone destructive changes. Hemilaminectomy showed to be effective for acute symptomatic relief and neurological improvement; radiotherapy has shown to be effective to maintain neurological status and prevent relapse. Further research is necessary to establish treatment recommendations.

## REFERENCES

1. Hans FJ, Geibrassert S, Krings T, et al. Solitary Plasmocytoma Presenting as an Intramedullary Mass of the Cervical Cord. *J Neurol Surg A*. 2013;74(Suppl 1):e13-e17.
2. Preston G, Anton T. T2 vertebrectomy with combined anterior and posterior arthrodesis for treatment of a solitary plasmocytoma. *Surg Neurol Int*. 2017;8:173.
3. Tsutsumi S, Yasumoto Y, Ito M. Solitary Spinal Extradural Plasmocytoma: A Case Report and Literature Review. *Clin Neuroradiol*. 2013;23(1):5-9.
4. Pinter NK, Pfiffner TJ, Mechtler LL. Neuroimaging of spine tumors. *Handb Clin Neuro*. 2016;136:689-706.
5. Lin P, Owens R, Tricot G, et al. Flow cytometric immunophenotypic analysis of 306 cases of multiple myeloma. *Am J Clin Pathol*. 2004;121(4):482-8.
6. Patriarca F, Zaja F, Silvestri F, et al. Meningeal and cerebral involvement in multiple myeloma patients. *Ann Hematol*. 2001; 80(12):758-62.
7. Faccioli F, Lima J, Bricolo A. One-stage decompression and stabilization of spinal tumors. *J Neurosurg Sci*. 1985;29(3):199-205.
8. Nakano H, Kato K, Nomura S, et al. A case of solitary plasmocytoma extending to the extradural space. *No Shinkei Geka*. 2017;45(9):811-7.
9. Palmbach M, Hoffmann W, Grodd W, et al. Extrasosseous, epidural tumor spread of multiple myeloma. *Eur J Radiol*. 1996;22(2):146-8.
10. Dispenzieri A, Kyle RA. Neurological aspects of multiple myeloma and related disorders. *Best Pract Res Clin Haematol*. 2005;18(4):673-88.
11. Benson WJ, Scarffe JH, Todd IDH, et al. Spinal-cord compression in myeloma. *BMJ*. 1979;1:1541-4.
12. El Khamary SM, Alorainy IA. Case 100: spinal epidural meningioma. *Radiology*. 2006;241(2):614-7.
13. Terada T. Solitary plasmocytoma of the thoracic vertebra presenting with sudden paraplegia and back pain: A pathologic case report. *Pathol Oncol Res*. 2011;17(1):167-9.
14. Yang JS, Cho YJ, Kang SH, et al. Rapid progression of solitary plasmocytoma to multiple myeloma in lumbar vertebra. *J Korean Neurosurg Soc*. 2013;54(5):426-30.
15. Knobel D, Zouhair A, Tsang RW, et al. Prognostic factors in solitary plasmocytoma of the bone: A multicenter Rare Cancer Network study. *BMC Cancer*. 2006;6:118.
16. Kumar A, Satyarthee GD, Sable M, et al. Solitary extramedullary plasmocytoma of thoracic epidural space presenting with dorsal compressive myelopathy: A case report and review of literature. *J Neurosci Rural Pract*. 2015;6(3):410-2.
17. Okacha N, Chrif E, Brahim E, et al. Extrasosseous epidural multiple myeloma presenting with thoracic spine compression. *Joint Bone Spine*. 2008;75(1):70-2.

18. Avadhani A, Shetty AP, Rajasekaran S. Isolated extraosseous epidural myeloma presenting with thoracic compressive myelopathy. *Spine J.* 2010;10(4):e7-e10.
19. Hu KC, Lin J, Chuang YC, Cheng SJ, et al. . *J Formos Med Assoc.* 200;100(4):277-80.
20. Lourbopoulos A, Ioannidis P, Balogiannis I, et al. Cervical epidural plasmacytoma presenting as ascending paraparesis. *Spine J.* 2011;11(5):e1-4.
21. Watanabe Y, Endou A, Ooi S, et al. Extraosseous epidural IgD myeloma presenting with compression myelopathy. *Psychiatry Clin Neurosci.* 2000;54(6):665-7.
22. Matsui H, Fujie H, Tsuji H. Extraosseous epidural tumor of immunoglobulin D myeloma. *J Spinal Disord.* 1992;5(3):366-9.